

NEW YORK-PRESBYTERIAN COLUMBIA ORTHOPAEDICS

Affiliated with COLUMBIA UNIVERSITY COLLEGE OF PHYSICIANS AND SURGEONS

Fall 2007

Case Study: New Prosthesis Saves Injured Shoulder

A 45-year-old female presented in early 2005 with a significant complicated shoulder injury. Until sustaining the injury to her right shoulder in a motorcycle accident, she was a very healthy woman. The injury resulted in a displaced and comminuted fracture of her proximal humerus and damage to her axillary nerve. She was initially treated nonoperatively but complications arose as the fracture failed to heal. The patient underwent an intramedullary nailing procedure that also failed to achieve union. She then underwent a second surgery that included removal of the nail, placement of a fresh frozen fibula allograft, and a plating procedure. During the postoperative period, the patient was maintained in a body cast, which also failed to achieve healing of the proximal humerus.

When the patient arrived at the Center for Shoulder, Elbow and Sports Medicine at NewYork-Presbyterian Hospital/Columbia University Medical Center, she had significant complaints of pain and was unable to perform routine functions. Her examination was notable for axillary-nerve injury affecting the anterior head of her deltoid, inability to raise her arm above her waist, and obvious motion at the site of fracture of the proximal humerus. In fact, the plate attached to her humerus was appreciated underneath

see Prosthesis, page 6

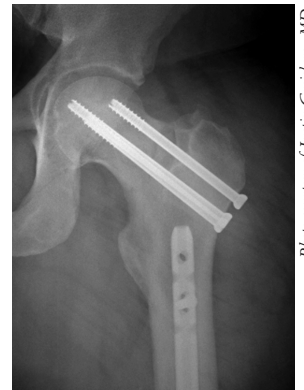New Technology Enhances Orthopaedic Trauma Center

There have been tremendous advances in the field of orthopaedic trauma in the last few decades. Thanks to improvements in implant technology and a vastly increased understanding of the biology of injuries, modern orthopaedic traumatologists are saving lives, saving limbs, and preserving function. The orthopaedic team at NewYork-Presbyterian Hospital/Columbia University Medical Center has taken a leadership role in many of these initiatives.

Take the case of a 40-year-old federal agent who sustained ipsilateral fractures of the neck and shaft of the femur during an automobile accident in upstate New York. The patient was transferred to NewYork-Presbyterian/Columbia for immediate surgery. The femoral neck was reduced, a capsulotomy was performed, and the fracture was stabilized with 3 screws. The shaft fracture was then treated with a retrograde intramedullary nail. A year after injury, he has returned to work and to the gym.

“Even in the recent past, we did not have good strategies for this combination of fractures,” said Justin Greisberg, MD. “It was not unusual to see a bad result. The newer technique of retrograde nailing of the femur fracture, combined with screw fixation of the femoral neck, is often very successful. Thirty years ago, this was a life-changing injury. Now, we can get people back to normal. That is what modern orthopaedic trauma care is all about.”

see Trauma, page 7



X-ray of the knee of an accident victim. Orthopaedic traumatologists at NewYork-Presbyterian/Columbia reduced the femoral neck, performed a capsulotomy, and stabilized the fracture with 3 screws.

Photo courtesy of Justin Greisberg, MD.

INSIDE

ACL Reconstruction

2 The orthopaedic team repairs a recurrent anterior cruciate ligament re-
tear in a college basketball player.

Knee Replacement

4 Procedures for total knee arthroplasty now include implants specially designed for women.

Scoliosis Surgery

5 Columbia orthopaedic surgeons use new technology and patient selection criteria to improve outcomes in the treatment of scoliosis in children.

Total Hip Resurfacing Webcast

For more information, please visit
www.nyp.org/columbiaortho

Questions, comments, suggestions?

Contact the Editor
Melvin P. Rosenwasser, MD
mpr2@columbia.edu

UPDATES

Case Study: Orthopaedic Team Revises a Failed ACL Reconstruction

The following case study describes a 21-year-old male varsity college basketball player at Columbia University who suffered a recurrent anterior cruciate ligament (ACL) re-tear. The patient presented at the Center for Shoulder, Elbow and Sports Medicine at NewYork-Presbyterian Hospital/ Columbia University Medical Center, under the care of William N. Levine, MD, who is Head Team Physician for the Columbia University Athletic Department. For the past 9 years, Dr. Levine has been responsible for the orthopaedic care of 29 varsity teams.

The Case

During his high school basketball career, this patient suffered a left knee ACL tear. In 2000, he underwent autologous hamstring ACL reconstruction. This surgical approach was consistent with best practices for a patient of this type.

According to Dr. Levine, “once an ACL has been torn, the best repair for an elite athlete is with an ACL reconstruction.” In the autologous hamstring ACL reconstruction, 2 tendons are taken from the patient’s hamstring and used as a substitute for the torn ACL. The substitute ligament is mechanically attached to bone using a screw, a pin, or both. The goal is to provide adequate fixation strength during rehabilitation, while the graft biologically integrates with the native bone.

After a 6-month rehabilitation, this patient returned to basketball and excelled as a high school player. He was recruited to play Division I basketball at Columbia University. During a game midway through his freshman season, the patient planted his left foot and twisted his previously injured left knee, which buckled and gave way.

Physical findings. Physical examination and MRI confirmed ACL graft rupture. The orthopaedic team faced the task of a revision ACL reconstruction, a more

complex and difficult surgery than the initial procedure.

Intervention. In planning the procedure, Dr. Levine anticipated multiple problems. First, revision procedures are always associated with decreased positive outcomes; statistically, they never have the success rate of primary reconstructions. Second, the previous surgery may complicate the revision, by the compromising of bone with previ-

“We have a better understanding of ACL anatomy, leading to a change in the surgical orientation of reconstructions and to the development of new hardware technologies.”

—William N. Levine, MD

ous hardware and grafting, by the creation of bone tunnels, and by the attachment requirements and biomechanical

effects of specific hardware used to fix the initial graft.

Finally, Dr. Levine noted, “the ability to return to the desired level of play after surgery was of great concern to the patient, as would be expected for an elite athlete playing Division I basketball.”

Outcome. The patient underwent an allograft revision ACL reconstruction, with a cross-pin technique on the femoral side. New tunnels were created to avoid interfering with tunnels from the first procedure. Screws made from biodegradable polymer and a bioceramic attached the graft to femoral and tibial bone.

After extensive rehabilitation, the athlete returned to his desired level of play. He is currently a contributing member of the Columbia University team.

Discussion

There have been many advances in ACL reconstruction over the past decade. Today, surgeons may select autologous grafts from patellar, hamstring, or quadriceps tendon, or may opt for an allograft taken from a cadaver.

“We have a better understanding of ACL anatomy, leading to a change in the surgical orientation of reconstructions and, above all, to the development of new hardware technologies,” noted Dr. Levine.


According to Dr. Levine, Christopher Ahmad, MD, and colleagues, for example,

Table. Performance of Femoral Fixation Devices

	Total Graft Slippage*	Fixation Failure Load†
Interference screw (N=9)	5.44 ± 3.25 mm	539 ± 114 N
EndoButton (N=8)	1.75 ± 0.97 mm	864 ± 164 N
Rigidfix cross-pin (N=8)	6.02 ± 2.12 mm	737 ± 140 N
Bio-Transfix cross-pin (N=8)	1.14 ± 0.53 mm	746 ± 119 N

* P<0.001 † P=0.0008

Source: Ahmad CS, et al. Am J Sports Med. 2004;32:635-640.



recently published a study showing that girls are 8 times more likely than boys to sustain injuries of the ACL while playing sports, in part because of muscle imbalances present only in girls (*Am J Sports Med* 2006;34:370-374). The study found that, following menarche, girls increase the muscle strength in their quadriceps more than the muscle strength in their hamstrings, leaving the ACL more vulnerable to tears.

Important research on various mechanical hardware devices has also been conducted by NewYork-Presbyterian/Columbia's Center for Shoulder, Elbow and Sports Medicine. For example, in 2004, clinicians from the Center—led by Drs. Ahmad and Levine and their team—published results of biomechanical research comparing several types of hardware for ACL reconstruction (*Am J Sports Med* 2004;32:635-640) (Table).

The hardware studied was developed to improve fixation of soft tissue grafts. Results showed that 2 devices may be preferred options for fixation because they reduce graft slippage: the Bio-Transfix cross-pin (Arthrex, Inc.; Naples, Fla), which allows the graft to be wrapped 180 degrees and held under tension around the pin, and the EndoButton (Smith & Nephew, Inc.; Andover, Mass), which seats the graft firmly against the femoral cortex. "These studies have been crucial in paving the way for the use of these new implant devices," said Dr. Levine. "They have provided a greater level of confidence in dealing with failures of soft tissue grafts, like the one suffered by the basketball player I treated."

Moreover, the studies have established the Center for Shoulder, Elbow and Sports Medicine at NewYork-Presbyterian/Columbia as a site of the best possible care for all patients—whether elite athletes or weekend warriors. All of the Center's physicians conduct basic science and clinical

NewYork-Presbyterian Columbia Orthopaedics

is a semi-annual newsletter published by NewYork-Presbyterian Hospital. The articles in this newsletter represent the work of the Columbia University faculty at NewYork-Presbyterian Hospital/Columbia University Medical Center, who are at the forefront of research and practice in the diagnosis, treatment, and rehabilitation of musculoskeletal conditions in adults and children.

NewYork-Presbyterian Columbia Orthopaedics Editorial Board

Melvin P. Rosenwasser, MD

Editor-in-Chief

Director, Hand and Orthopaedic Trauma Services

NewYork-Presbyterian/Columbia

Robert E. Carroll Professor of Orthopaedic Surgery

Columbia University College of Physicians and Surgeons

mpr2@columbia.edu

Louis U. Bigliani, MD

Chief, Orthopaedic Surgery Service and Director,

Center for Shoulder, Elbow and Sports Medicine

NewYork-Presbyterian/Columbia

Frank E. Stinchfield Professor and Chairman

Department of Orthopaedic Surgery

Columbia University College of Physicians and Surgeons

lub1@columbia.edu

Francis Y. Lee, MD

Chief, Tumor and Bone Disease Service

NewYork-Presbyterian/Columbia

Associate Professor of Orthopaedic Surgery

Director, Center for Orthopaedic Research

Columbia University College of Physicians and Surgeons

fl127@columbia.edu

William N. Levine, MD

Director, Sports Medicine

Associate Director, Center for Shoulder,

Elbow and Sports Medicine

NewYork-Presbyterian/Columbia

Vice Chairman and Professor of Clinical Orthopaedic Surgery

Columbia University College of Physicians and Surgeons

wnl1@columbia.edu

William B. Macaulay, MD

Director, Center for Hip and Knee Replacement

NewYork-Presbyterian/Columbia

Associate Professor of Orthopaedic Surgery

Columbia University College of Physicians and Surgeons

wm143@columbia.edu

Christopher B. Michelsen, MD

Chief, Orthopaedic Spine Service

NewYork-Presbyterian/Columbia

Chief, Orthopaedic Surgery

The Allen Pavilion of NewYork-Presbyterian Hospital

Professor of Clinical Orthopaedic Surgery

Columbia University College of Physicians and Surgeons

cbmmd@yahoo.com

David P. Roye, MD

Chief, Pediatric Orthopaedic Surgery

Morgan Stanley Children's Hospital of

NewYork-Presbyterian/Columbia

St. Giles Professor of Pediatric Orthopaedic Surgery

Columbia University College of Physicians and Surgeons

dpr2@columbia.edu



research, educate residents and fellows, and practice clinically, with some also serving as team physicians.

"Our physicians," said Dr. Levine, "have dedicated their careers to improving ACL reconstruction and other sports medicine procedures. This is a renowned sports medicine center that leads the field."

Christopher Ahmad, MD, is Assistant Attending Orthopaedic Surgeon, and Associate Director, Center for Shoulder, Elbow and Sports Medicine at NewYork-Presbyterian Hospital/Columbia University Medical Center, Director of the Center for Pediatric and Adolescent Sports Medicine at Morgan Stanley Children's Hospital of

NewYork-Presbyterian/Columbia, and is Associate Professor of Orthopaedic Surgery at Columbia University College of Physicians and Surgeons. E-mail: csa4@columbia.edu.

William N. Levine, MD, is Director, Sports Medicine and Associate Director, Center of Shoulder, Elbow and Sports Medicine at NewYork-Presbyterian Hospital/Columbia University Medical Center, and is Head Team Physician for the Columbia University Athletic Department, and is Vice Chairman and Professor of Clinical Orthopaedic Surgery at Columbia University College of Physicians and Surgeons. E-mail: wnl1@columbia.edu.

Better Fit, Early Recovery: Knee Implants Designed for Women

Procedures for total knee arthroplasty (TKA) at NewYork-Presbyterian Hospital/Columbia University Medical Center now include implants specially designed for women. Early results suggest enhanced patient satisfaction and possibly earlier than usual postoperative recovery of range of motion, which is a sign of long-term success.

“I believe that there are merits to it,” said Jeffrey Geller, MD, who has, to date, performed several dozen procedures involving the gender-specific implant. “It’s almost exclusively the knee that I’ve been [performing implants on in] women since it came out several months ago.”

In terms of patient demographics, the advent of a distaff knee should not come as a surprise. Of the approximately 400,000 implants performed annually, nearly two thirds are for women. For both men and women, the number of total knee replacements is rising, reflecting the aging yet active population of post-World War II baby boomers. The recent introduction of less-invasive procedures, like partial knee replacement and gender-specific knee replacement, have made replacement procedures a more amenable option for many patients. The risk of arthritis and related diseases in older adults should make the operation even more common in years to come.

“We’re seeing arthritis earlier in people and we’re becoming more aggressive in treating it,” said Dr. Geller.

Several anatomic differences distinguish the female knee and surrounding structures. The shape of the female femur, which is somewhat different from the male femur, is generally narrower along the medial to lateral plane but wider from front to back. Working with conventional implants, surgeons often need to manually compensate for this difference to improve the replacement fit in women patients.

“Because we usually measure the femur from the front to the back when we’re sizing an implant, if the femur is narrower

side to side, you may get some overhang on the implant,” said Dr. Geller. A tendency to use a device slightly larger than necessary can have undesirable clinical implications, including pain to the collateral ligaments and an “overstuffed” knee that feels tighter to the patient. “In the past, during surgery I have had to slightly alter the desired position of the implant and use a smaller than normal size for a female knee.” This can work, he added, “but you worry that you can affect the patient’s range of motion, the position of

angle is larger than in men, and the new prosthesis reflects that difference. Also important is the high-flex design of the posterior part of the knee, which has been shown to result in increased ultimate range of motion.

Early results for the new knee are encouraging. Studies to test distinctive improvement can only be expected in the long-term, but meanwhile, anecdotal reports tend to be favorable. One of Dr. Geller’s patients, a 78-year-old female, underwent the procedure for the right knee and described a fairly typical recovery with physical therapy, home use of ice compresses, and follow-up exercises that she still performs.

“I was able to drive with confidence within 5 weeks and now I’m able to get around quite well,” said the patient. She estimated that range of motion was nor-

A design characteristic that makes the gender-specific knee more suited to female anatomy is the “Q” angle. In women with wider hips, the Q angle is larger than in men, and the new prosthesis reflects that difference.

the implant, and whether or not you risk periprosthetic fractures as a result of notching the femur.” The new implant obviates these dangers.

Quantitative analysis of the morphological features of the human knee helped to develop the basic fit of the gender-specific prosthesis. Generally, in the evolution of orthopaedic procedures, reconstructions that more closely match the natural anatomy seem to do better, according to Dr. Geller. However, procedures are not as a rule gender-designed, making the knee an exception. Shoulders for female patients may use smaller sizes, for example, but they have never been marketed or designed specifically with women in mind.

Another design characteristic to make the gender-specific knee more suited to female anatomy is the quadriceps or “Q” angle. In women with wider hips, the Q

mal at “about 98%.” While continuing prescribed stretching exercises, she acknowledges tightness across the knee. She was pleased by the elimination of both pain and deformity due to arthritis. “My leg is perfectly straight. I look at it with great pleasure.”

Patients receiving TKA are often still in the workforce and many may be expected to outlive their first implant and require revision surgery. “Patients who undergo this operation today tend to be younger and more active and they expect more out of an implant,” said Dr. Geller.

Jeffrey Geller, MD, is Director, Minimally Invasive Joint Replacement Surgery at NewYork-Presbyterian Hospital/Columbia University Medical Center, and is Assistant Professor of Orthopaedic Surgery at Columbia University College of Physicians and Surgeons. E-mail: jg2520@columbia.edu.

Hospital Surgeons Use New Technology To Improve Outcomes in Pediatric Scoliosis Surgery

Russell Hibbs, MD, an orthopaedic surgeon who was a professor at Columbia University College of Physicians and Surgeons in the early years of the 20th century, pioneered surgical treatments for scoliosis, performing the first operation in 1914, just 3 years after his first-ever spinal fusion in a patient with Pott's disease (tuberculosis of the spine).

Dr. Hibbs' procedure, highly controversial at the time, involved stripping the periosteum from the posterior arches, splitting the spinous processes so that they might overlap the interspinous spaces, and inserting fragments of bone

technology, a lengthy postoperative period of restricted movement is no longer required. Most surgery for scoliosis entails a 4-day hospital stay; return to school is possible within 2 weeks, and participation in active sports after several months.

"That is much different than in the past," said Dr. Vitale, who is the Chief of the Pediatric Spine and Scoliosis Service at the Morgan Stanley Children's Hospital of NewYork-Presbyterian. "Patients generally get back to normal activities much more quickly."

Current methods and instrumentation, which have replaced internal fixation with the Harrington rod (introduced in the

not candidates for spinal fusion.

Early-onset scoliosis is a particular interest of the pediatric spine surgeons at Morgan Stanley Children's Hospital of NewYork-Presbyterian, who have been involved in the innovation of treatment options for young children with scoliosis.

"Everyone feels strongly that we should not be performing fusion in young kids, under 7 or 8 years old," said Dr. Vitale. "The lungs require a certain amount of space to develop, and if they don't have that space early on in life, they just don't develop."

New options include the use of "growing rods" that can be periodically lengthened as the patient grows. Today, improved aspects of this procedure include dual-rod instrumentation, polyaxial screws, and undersized and hybrid implants.

Current investigations, still at the pre-clinical stage, relate to servomechanisms and internally implanted motors that may be used to lengthen the growing rods without further surgical intervention, according to Columbia researchers at Morgan Stanley Children's Hospital of NewYork-Presbyterian.

The VEPTR (vertical expandable prosthetic titanium rib) is an even newer treatment option for children with early-onset scoliosis. Dr. Vitale and David P. Roye, MD, have spearheaded the implementation of the VEPTR at Morgan Stanley Children's Hospital of NewYork-Presbyterian, making it a regional center for the use of this novel device, which in essence enables lung growth while correcting scoliosis. The VEPTR consists of a telescoping rod with a hook on either end for attachment to the child's ribs. The device allows surgeons to open the chest cavity to provide more room for lung growth.

Historically, thoracic insufficiency syndrome has been treated by fusing together vertebrae of the spine, causing stunted growth in many cases. According to Dr. Roye, however, "the VEPTR offers several significant advantages to young

see Scoliosis, page 6

According to Michael G. Vitale, MD, new techniques of segmental fixation enable "better correction of spinal deformity without postoperative immobilization." Rotational deformity can be rectified, and proper lumbar lordosis maintained.

into the interlaminar spaces. When in 1924 he reported on a series of 59 patients, Dr. Hibbs had obtained generally good results in children aged 3 1/2 to 9 years. Still, for decades, recovery from spinal fusion was long and arduous. After surgery, young patients were fitted with a traction jacket that they wore for 6 weeks while remaining immobile in bed. They then wore a removable jacket for the next 6 to 12 months.

Today, Columbia surgeons at Morgan Stanley Children's Hospital of NewYork-Presbyterian are still pioneering surgical approaches to scoliosis, leading the way in the use of "third-generation" instrumentation that facilitates recovery and improves outcomes for both adolescents and younger children.

According to Michael G. Vitale, MD, when surgery is performed with the new

1960s by Paul Harrington, MD), enable surgeons to greatly improve alignment and restore a normal degree of kyphosis (bending forward of the thoracic spine) and lordosis (bending backward of the lumbar spine). Implanted rods are connected to the spine by hooks, wires, and pedicle screws.

According to Dr. Vitale, new techniques of segmental fixation enable "better correction of spinal deformity without postoperative immobilization." Rotational deformity can be rectified and proper lumbar lordosis maintained.

Scoliosis can also occur in very young children—even from birth. This frequently arises from a congenital difference, a syndrome, or a neuromuscular disorder. These patients, who often also have poor lung function as a result of the effect of the scoliosis on the chest and lungs, are

Prosthesis

continued from page 1

her skin and tented the skin with attempts to forward elevate. An electromyogram and nerve conduction study confirmed damage to the axillary nerve.

In summary, the patient was a healthy,

of shoulder replacement with a trabecular metal coating.

“The features of this new trabecular metal are that it allows bone healing into the metal,” said Christopher Ahmad, MD. “Given her lack of healing and loss of bone with previous standard approaches,

osteotomy of the humeral head and tuberosities, and osteosynthesis of tuberosities.

Following surgery, the patient was noted to have progressive and significant relief of her pain, and with time and physical therapy, she began regaining motion in her shoulder. Almost 2 years later, she can lift her arm over her head and she performs routine activities such as grocery shopping and getting dressed. X-rays demonstrate union of her fracture and bone healing to the trabecular metal as well as to the humeral shaft.

“This new trabecular metal allows bone healing into the metal. Given [the patient’s] loss of bone with standard approaches, this option provided the most predictable ability to facilitate healing.”

— Christopher Ahmad, MD

Discussion

Trabecular metal, fabricated with elemental tantalum, has a cellular structure that resembles bone and is 80% porous. This structure encourages bone formation and tissue ingrowth. Because surgeons prefer to minimize the replacement of native bone in younger patients, trabecular metal prostheses are mostly used for hip replacements and other surgeries more common in older patients.

In the case presented here, however, the patient’s numerous operations had resulted in significant bone loss, so a prosthesis was needed and trabecular metal seemed the best choice.

“Patients who have 4-part proximal humerus fractures are referred immediately for shoulder replacement,” said

see Prosthesis, page 8

active woman devastated by constant pain and poor function despite multiple surgical attempts at correction. The situation was complicated by significant remaining hardware, nerve injury, loss of bone, immense scar tissue, and nonunion of bone.

Given the bone loss, failure of fixation with allograft augmentation, and failure of state-of-the-art plating systems, the patient was offered the option

this option provided the most predictable ability to facilitate healing, thereby providing pain relief and improved function.”

After the prosthesis stem was manufactured and completed, the patient underwent surgery. It should be noted that this was the first application of the long-stem trabecular metal prosthesis. The lengthy operation required hardware removal, extensive lysis of adhesions near her brachial plexus, placement of the stem,

Scoliosis

continued from page 5

patients with scoliosis, but this program requires the multidisciplinary strengths of an institution like ours.”

Research published by Dr. Vitale and colleagues (*J Pediatr Orthop* 2005;25:393-399) has shown a volume–outcome relationship in scoliosis surgery. The retrospective review of 3,606 cases showed that patients treated in hospitals at which 5 or fewer scoliosis procedures are performed annually were twice as likely to require a second operation. Surgeons at Morgan Stanley Children’s Hospital of NewYork-Presbyterian perform approximately 125 such procedures every year.

“Everyone feels strongly that we should not be performing fusion in young kids, under 7 or 8 years old. The lungs require a certain amount of space to develop, and if they don’t have that space early on in life, they just don’t develop.”

—Michael G. Vitale, MD

David P. Roye, MD, is Chief, Pediatric Orthopaedic Surgery at the Morgan Stanley Children’s Hospital of NewYork-Presbyterian/Columbia University Medical Center, and is St. Giles Professor of Pediatric Orthopaedic Surgery at Columbia University College of Physicians and Surgeons. E-mail: dpr2@columbia.edu.

Michael G. Vitale, MD, is Chief, Pediatric Spine and Scoliosis Service at Morgan Stanley Children’s Hospital of NewYork-Presbyterian, and is Ana Lucia Associate Professor of Orthopaedic Surgery at Columbia University College of Physicians and Surgeons. E-mail: mgv1@columbia.edu.

Trauma

continued from page 1

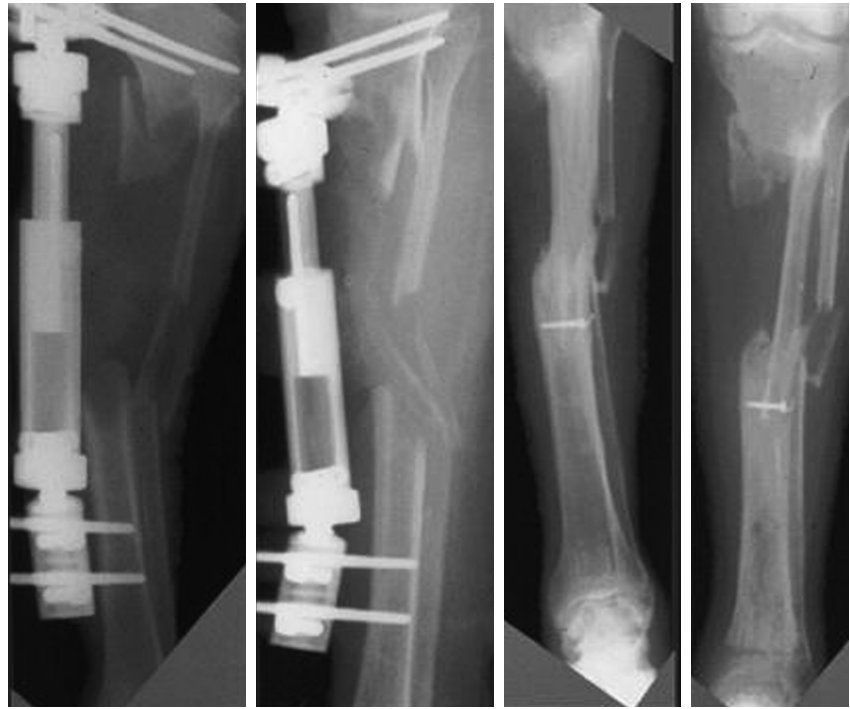
Although much has changed, the current service for orthopaedics and orthopaedic trauma at NewYork-Presbyterian/Columbia has a long and distinguished history. The unit is the successor to the New York Orthopaedic Hospital (NYOH), established in 1866 to treat poor children with diseases of the musculoskeletal system. A fracture service was instituted early in the 20th century, and NYOH merged with the Presbyterian Hospital Trauma Service in 1945. In 1950, it became affiliated with the Columbia Presbyterian Medical Center. Today, equipped with the personnel and equipment for treating patients with critical injuries, orthopaedic trauma specialists at NewYork-Presbyterian Hospital/Columbia seek out all cases of musculoskeletal injury that can benefit from their unique level of expertise.

“We are here to take on all comers, to deal with very severe injuries.”

—Melvin P. Rosenwasser, MD

“We are here to take on all comers, to deal with very severe injuries, some of which would cost a patient’s life or limb,” said Melvin P. Rosenwasser, MD. “We welcome our orthopaedic colleagues to look upon us as a resource.” Noting that except for Morgan Stanley Children’s Hospital, NewYork-Presbyterian/Columbia has not officially been designated a Level 1 Trauma Center, Dr. Rosenwasser added, “all we’re missing is the actual designation. For every aspect of Level 1 care, this is the place to be.” Work has begun to formally achieve Level 1 designation.

Modern-day, high-energy trauma includes a mix of motor vehicle and pedestrian accidents, as well as sporting injuries from such sports as skiing and



Photos courtesy of Melvin P. Rosenwasser, MD.

Case study pre-op (left): X-rays (AP/Lat) after debridement of grade IIIIB open tibia with 15 cm loss of substance. Case study follow-up (right): X-rays (AP/Lat) post-reconstruction in 1 stage using an osteocutaneous vascularized fibular graft, which shows union and hypertrophy of the graft at 1 year with excellent function.

horseback riding. Unfortunately, the urban environment continues to bring in falls from a height, which create the worst peri-articular fractures. The result of these accidents is fractures with tremendous soft tissue injury. “It’s not just bones,” Dr. Rosenwasser explained. “It’s joints, the way the bones move, their architecture, and the soft tissues that cloak them. Nerves, muscles, ligaments, and bones all take the impact. It’s a whole constellation of injuries.”

Optimal and timely care for patients with such injuries, often multiple, requires orthopaedic physicians and surgeons to operate in concert with other specialists who, working in close proximity, are accessible for consultation and collaboration. Orthopaedic trauma at NewYork-Presbyterian/Columbia functions in just such an environment. The Division of Orthopaedic Trauma also includes the Trauma Training Center (TTC), founded in 1992, which provides both an educational arm and an operational base. The TTC archives clinical information and fosters both clinical trials and basic research, emphasizing evidence-based medicine. The TTC, which includes state-of-the-art laboratories and boasts an international staff, represents the full range of capabilities of the trauma unit and its larger aspirations.

“We are in the middle of a major research and teaching university setting and gain much from the immediate contact and ability to draw on all these experts, in the same building, on the same floor,” said Dr. Rosenwasser. “We created this center specifically to look at controversial issues in orthopaedic trauma. We’re advancing the science behind the specialty to improve our knowledge base, to give surgeons best practices to follow and justification for what they do. We have all the pieces of these puzzles, and we’re manipulating those pieces to try to move the orthopaedic trauma world forward.”

Justin Greisberg, MD, is Attending Surgeon at NewYork-Presbyterian Hospital/Columbia University Medical Center, and is Assistant Professor of Orthopaedics at Columbia University College of Physicians and Surgeons. E-mail: jkg2101@columbia.edu.

Melvin P. Rosenwasser, MD, is Director, Hand and Orthopaedic Trauma, and Microsurgery Services at NewYork-Presbyterian Hospital/Columbia University Medical Center, and is Robert E. Carroll Professor of Orthopaedic Surgery at Columbia University College of Physicians and Surgeons. E-mail: mpr2@columbia.edu.

Prosthesis

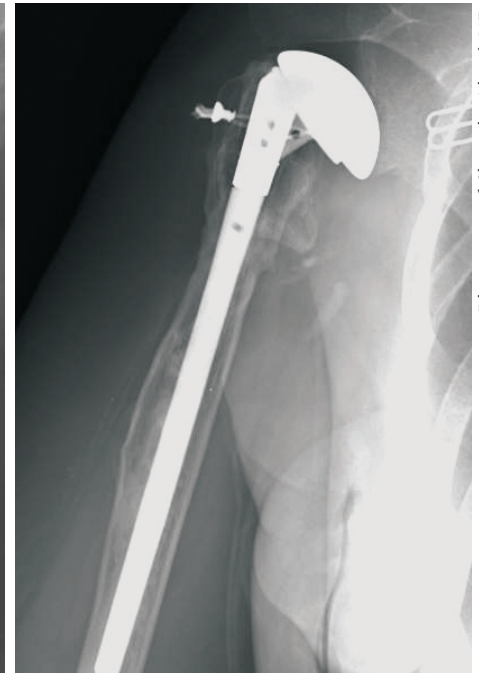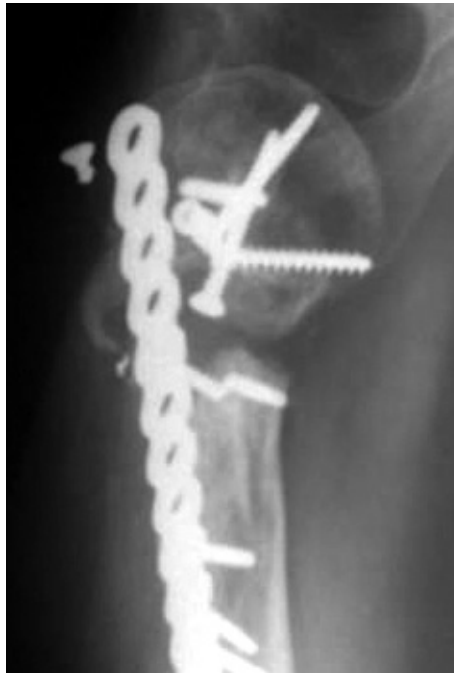continued from page 6

Dr. Ahmad. “The blood supply to the humeral head is compromised, so the head is going to become necrotic, requiring replacement right away. A major issue

X-rays demonstrate union of her fracture and bone healing to the trabecular metal as well as to the humeral shaft.

with doing the humeral head replacement is getting the tuberosities to heal to the shaft. If that bone doesn’t heal, the patient has very poor function. The trabecular metal enhances the healing of that bone, so it’s much improved with this operation.”

The technology for this particular prosthesis was newly developed and required the patient to wait 6 months for surgery—despite being in extreme pain—until a stem could be manufactured. Initially, Dr. Ahmad looked into having a piece custom-made for the patient, but the manufacturers decided instead to



Photos courtesy of Christopher Ahmad, MD.

X-ray of a trabecular metal prosthesis for proximal humerus fracture. NewYork-Presbyterian/Columbia orthopaedic surgeons have found the trabecular metal prosthesis to be a cost-effective, and effective, option.

begin mass production. The patient received the first standardized piece they produced. The surgical techniques used also had to be customized for the new type of prosthesis.

Despite its novelty, Dr. Ahmad noted that the trabecular metal stem is not cost prohibitive for either the patient or the Hospital. He added, “If the patient has a failed operation and then needs multiple future operations, or if they then have a disability where they can never get back to work, the value of the prosthesis in that situation far outweighs its cost.”

Christopher Ahmad, MD, is Assistant Attending Orthopaedic Surgeon, and Associate Director, Center for Shoulder, Elbow and Sports Medicine at NewYork-Presbyterian Hospital/Columbia University Medical Center, Director of the Center for Pediatric and Adolescent Sports Medicine at Morgan Stanley Children’s Hospital of NewYork-Presbyterian/Columbia, and is Associate Professor of Orthopaedic Surgery at Columbia University College of Physicians and Surgeons. E-mail: csa4@columbia.edu.

NewYork-Presbyterian Hospital • Columbia University College of Physicians and Surgeons

NEW YORK - PRESBYTERIAN
COLUMBIA ORTHOPAEDICS

Important news from NewYork-Presbyterian/Columbia Orthopaedics, at the forefront of research and practice in the diagnosis, treatment, and rehabilitation of musculoskeletal conditions in adults and children.

Fall 2007

NewYork-Presbyterian Hospital
622 West 168th Street
New York, NY 10032

NONPROFIT ORG.
U.S. Postage PAID
Permit No. 37
Utica, NY