Target Delineation for Prostate Cancer

Michael J Zelefsky M.D.
Professor of Radiation Oncology
Chief, Brachytherapy Service
Memorial Sloan Kettering Cancer Center

Keys for Successful Contouring

- Familiarity with the target anatomy
- Understanding the extent of disease and areas at risk for microscopic extension
- Familiarity with the juxtaposed normal tissue structures

Zonal Anatomy

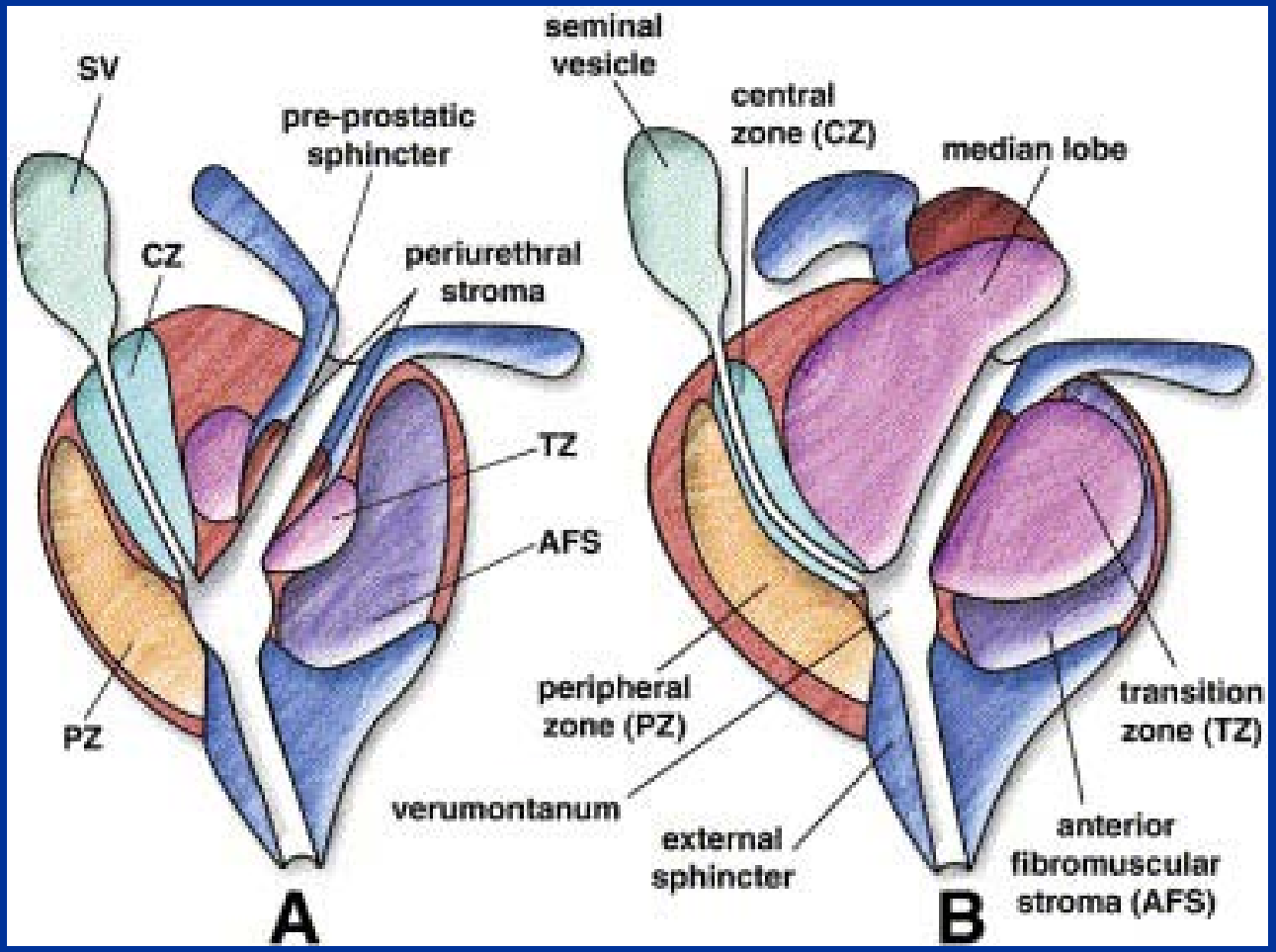

Saggital View

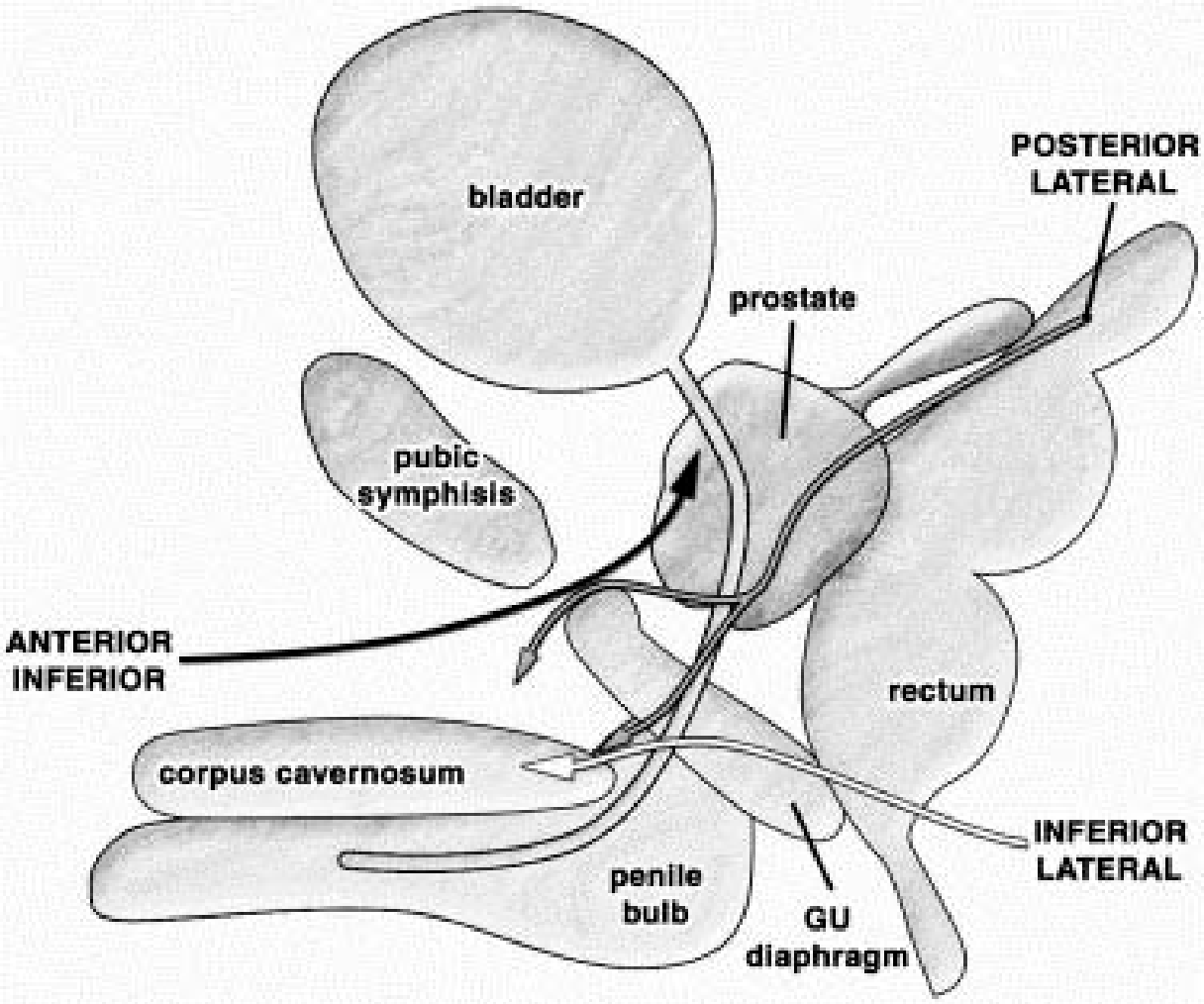

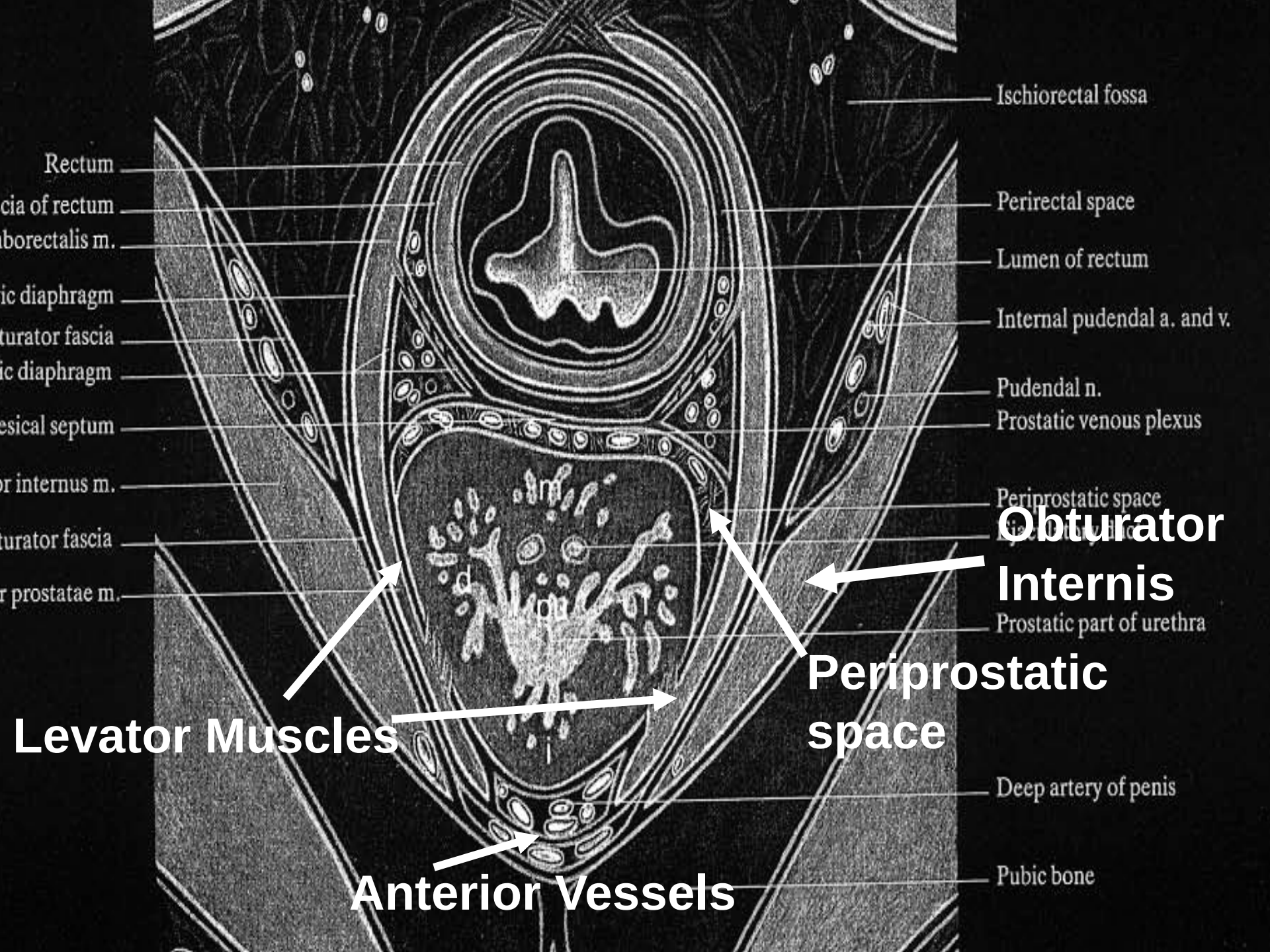
Ischiorectal fossa
Rectum
cia of rectum
borectalis m.
ic diaphragm
turator fascia
ic diaphragm
esical septum
r internus m.
turator fascia
r prostatae m.
Perirectal space
Lumen of rectum
Internal pudendal a. and v.
Pudendal n.
Prostatic venous plexus
Periprostatic space
Prostatic part of urethra
Deep artery of penis
Pubic bone
Obturator Internis
Periprostatic space
Levator Muscles
Anterior Vessels

Anatomy of Imaging

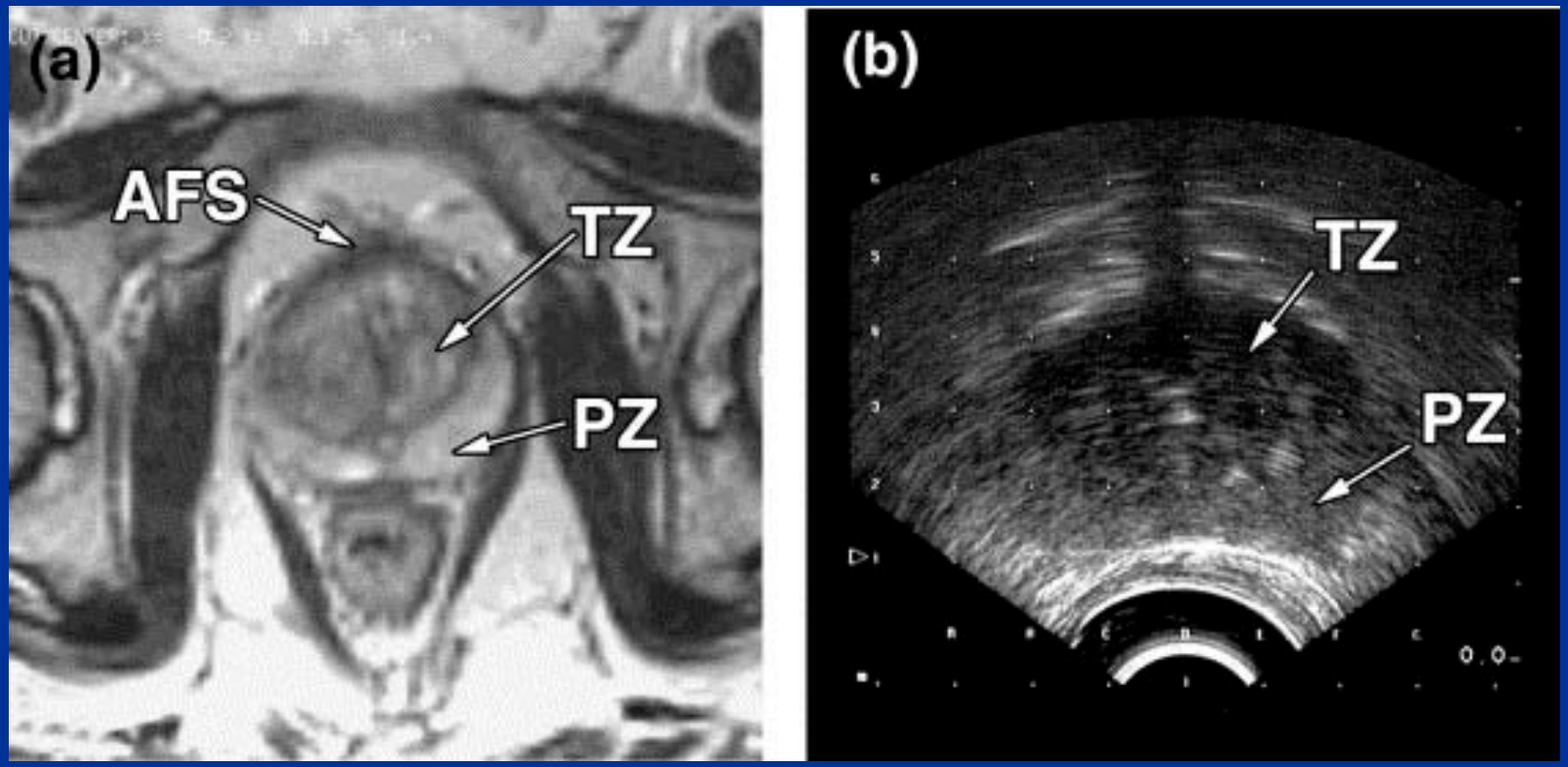

IMRT @ MSKCC: Target Volume Definitions

Clinical Target Volume (CTV)

Prostate and seminal vesicles (SV)
Regional lymph nodes included for high risk disease

Planning Target Volume (PTV)

1 cm margin around CTV
Rectal-prostate interface - 6 mm margin only
Superior border at tips of the SV

Inferior border above penile bulb

Treatment Volume

PTV plus 5 mm except 10 mm at superior and inferior aspects to account for penumbra

IMRT @ MSKCC: Target Volume Definitions With Fiducial Markers

Planning Target Volume (PTV)

- **6mm margin around CTV**
  - ***3mm posterior margin used for hypofractionated treated patients and seeded patients receiving supplemental EBRT***
- **Superior border at tips of the SV**
- **Inferior border above penile bulb**
  - ***prostate apex generally 1.2 cm above the penile bulb***

Simulation and Treatment Conditions

- Empty rectum (bowel prep for sim)
- Empty bladder
- Fiducial markers placed 3-5 days before simulation
- Calypso used for hypofractionated patients
- Aquaplast immobilization

IMRT: Dose Prescription and Delivery

Dose Prescription

PTV encompassed by 100% isodose line
Isocenter dose (ICRU dose) 5-7% higher
Hot spots in the range 109-111%

Dose/Volume Restriction

≥30% of rectal wall carried to 75.6 Gy

53% of rectal wall not receiving more than 47 Gy

For patients treated to 81 Gy- max rectal wall dose 83.4 Gy

≥ 50% of bladder wall carried to prescription dose

Maximal large bowel dose - < 60 Gy

Full Bladder Conditions

- All post-op cases
- Small bladder volume or small capacity where greater bladder sparing is necessary

Mid-Gland- CTV Only

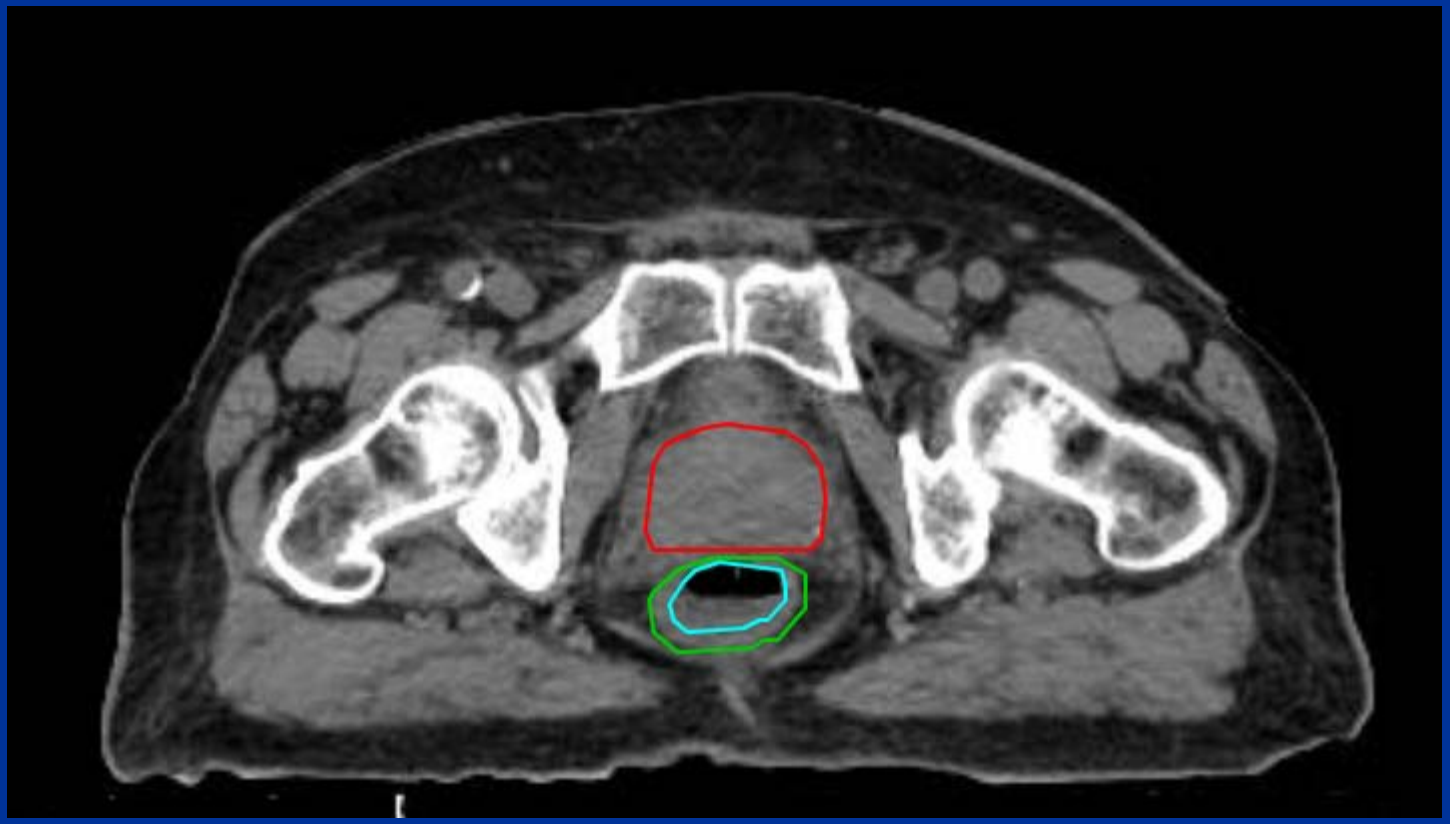

Mid-Gland- with PTV

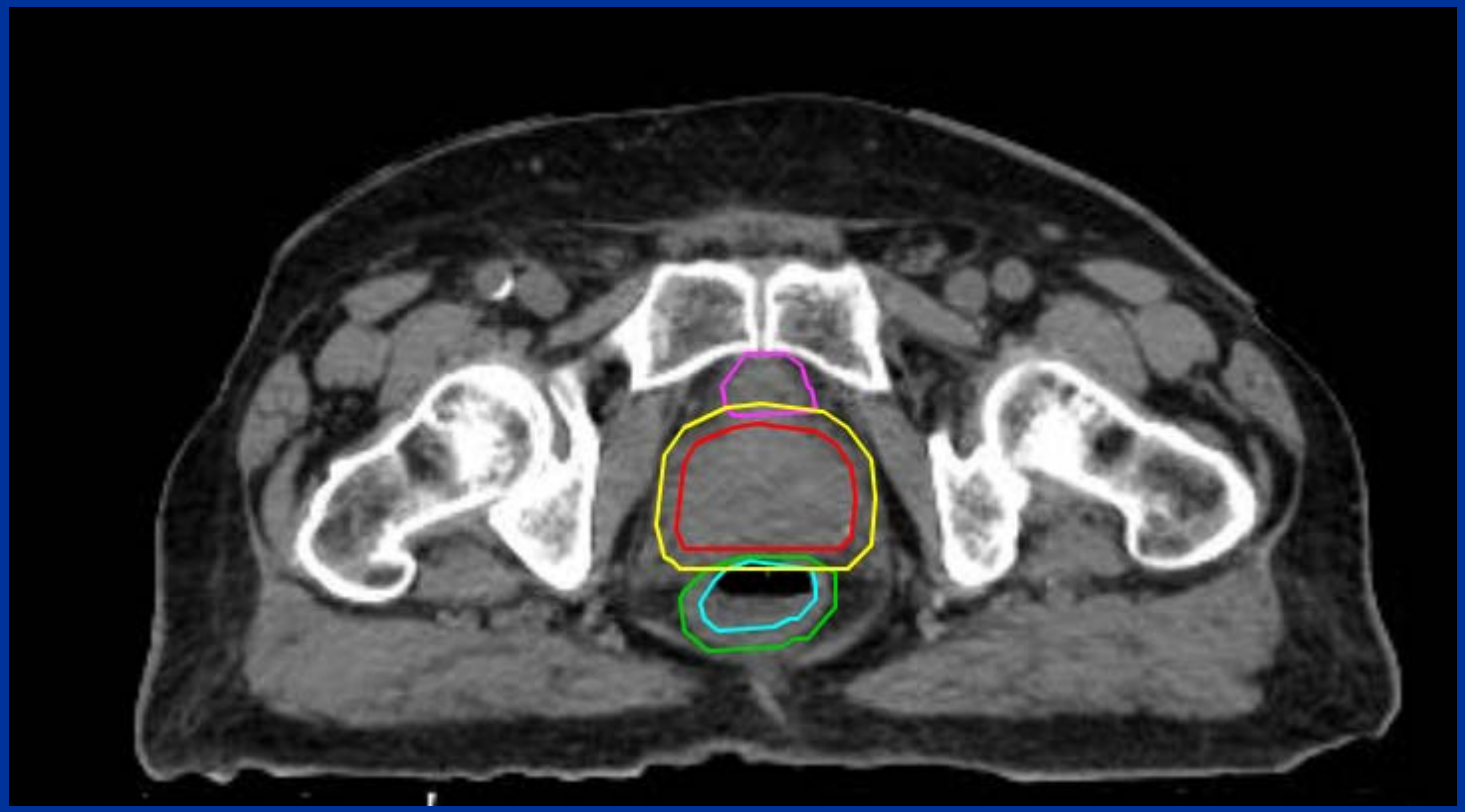

Near Apex- CTV only

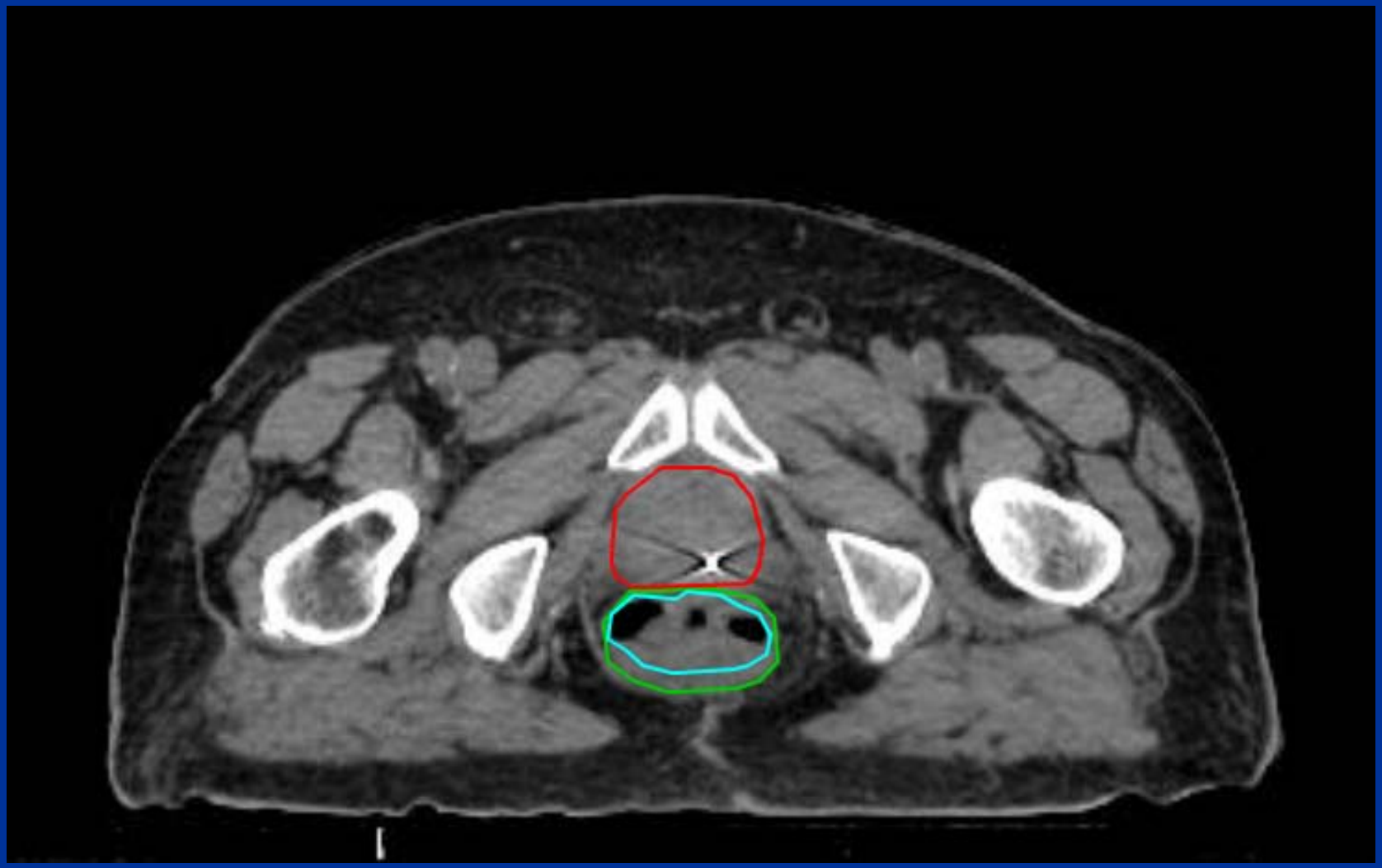

Near Apex- With PTV

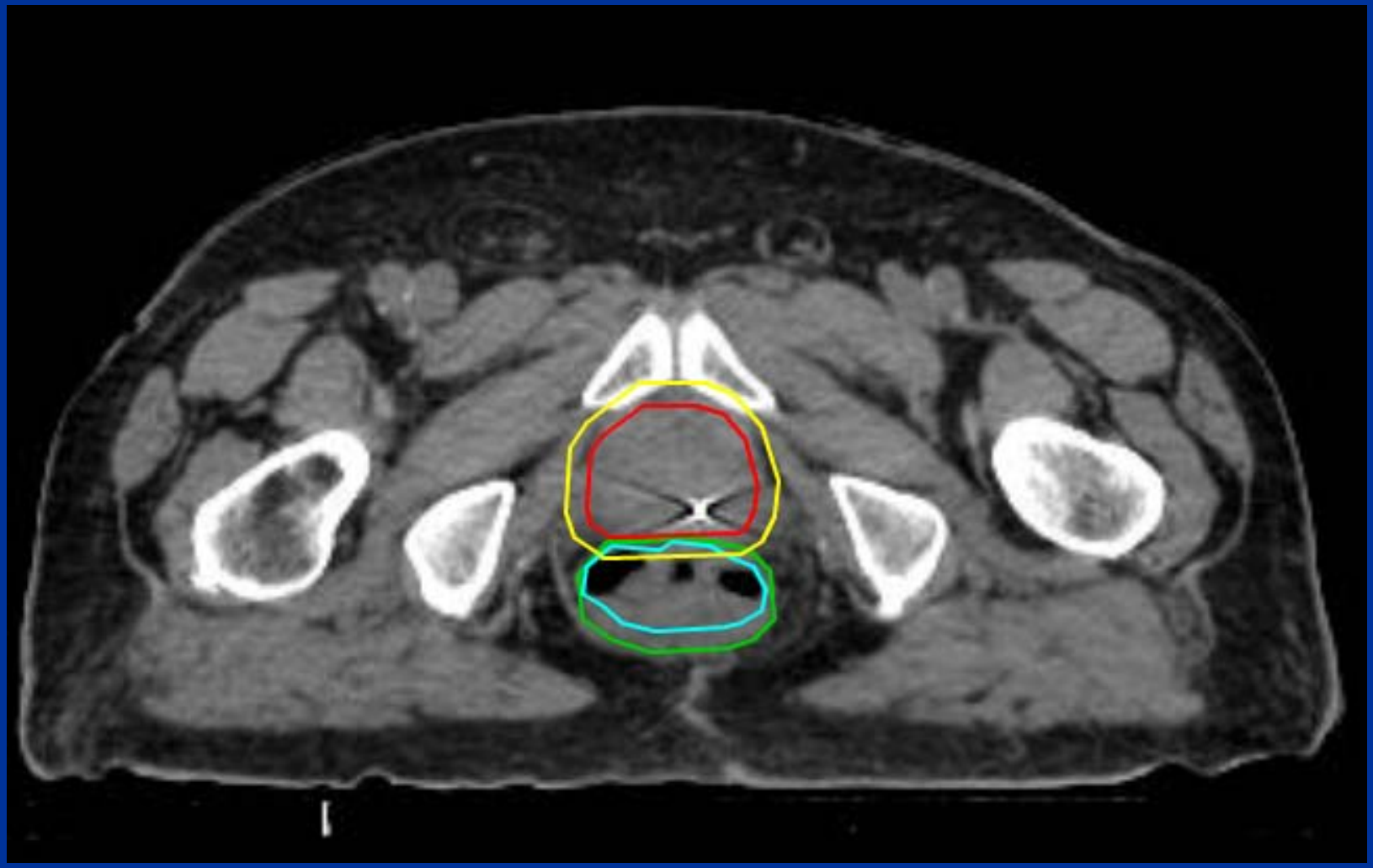

Towards the Base- CTV Only

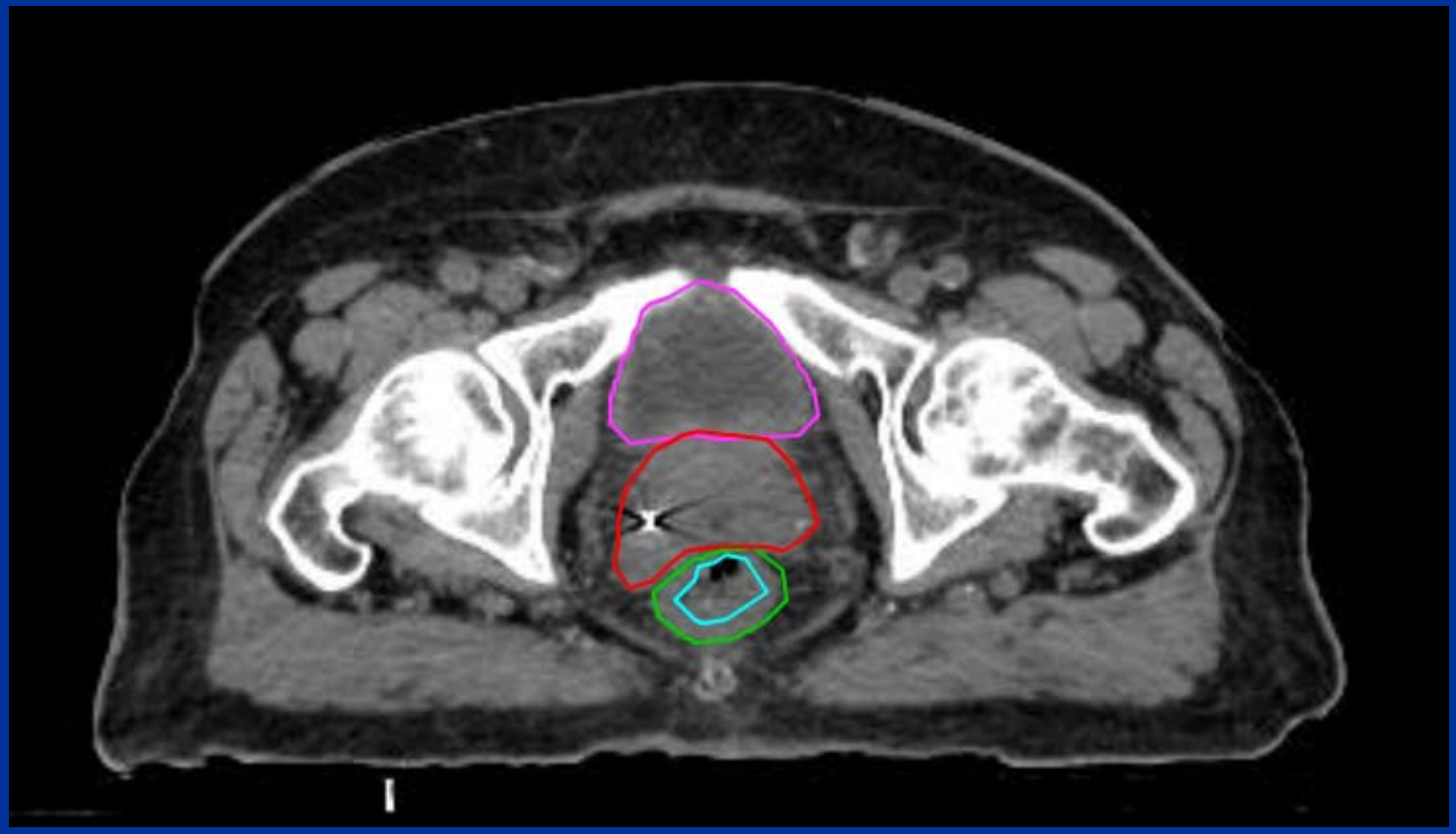

Towards the Base with PTV

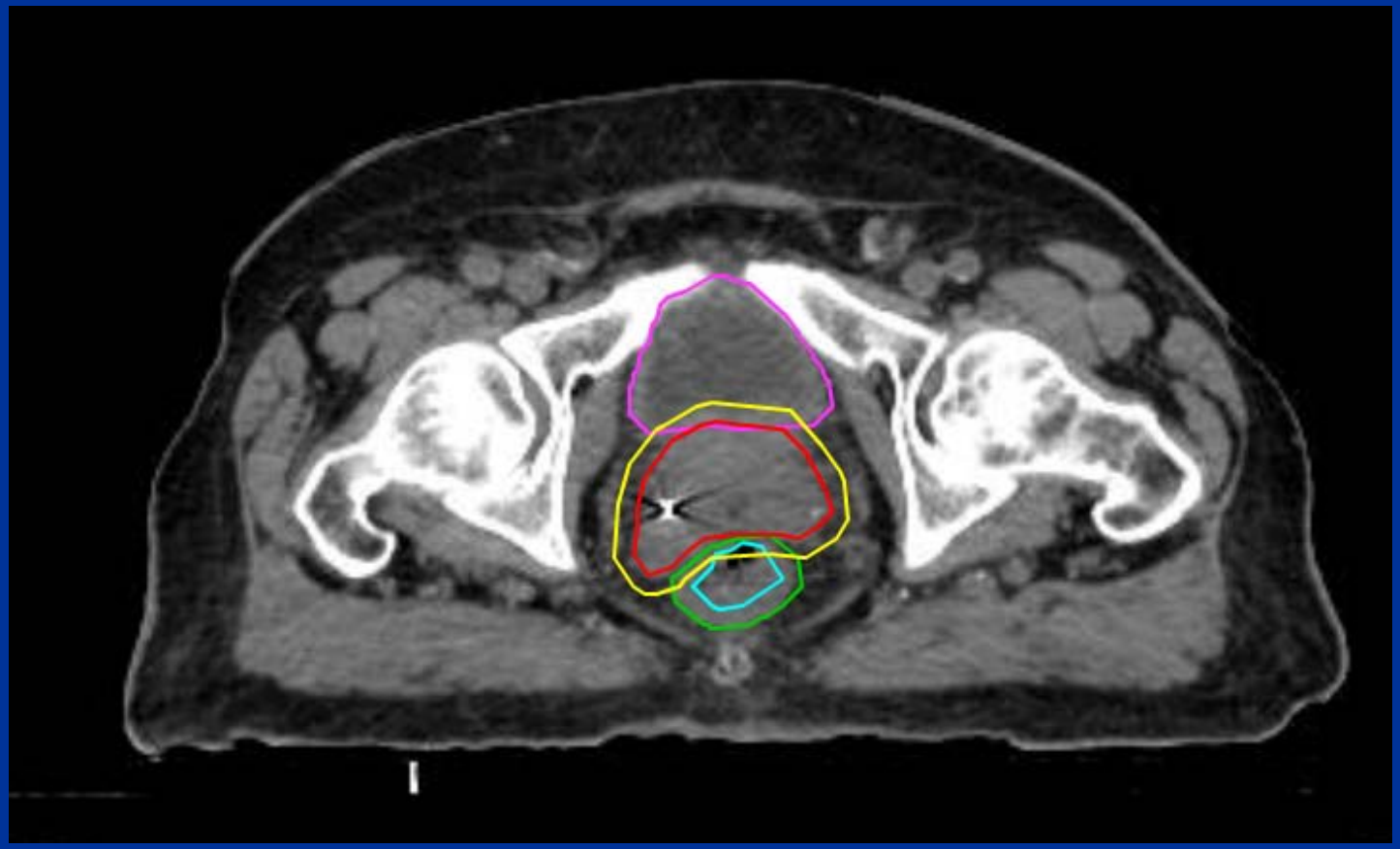

At the Level of SV- CTV only

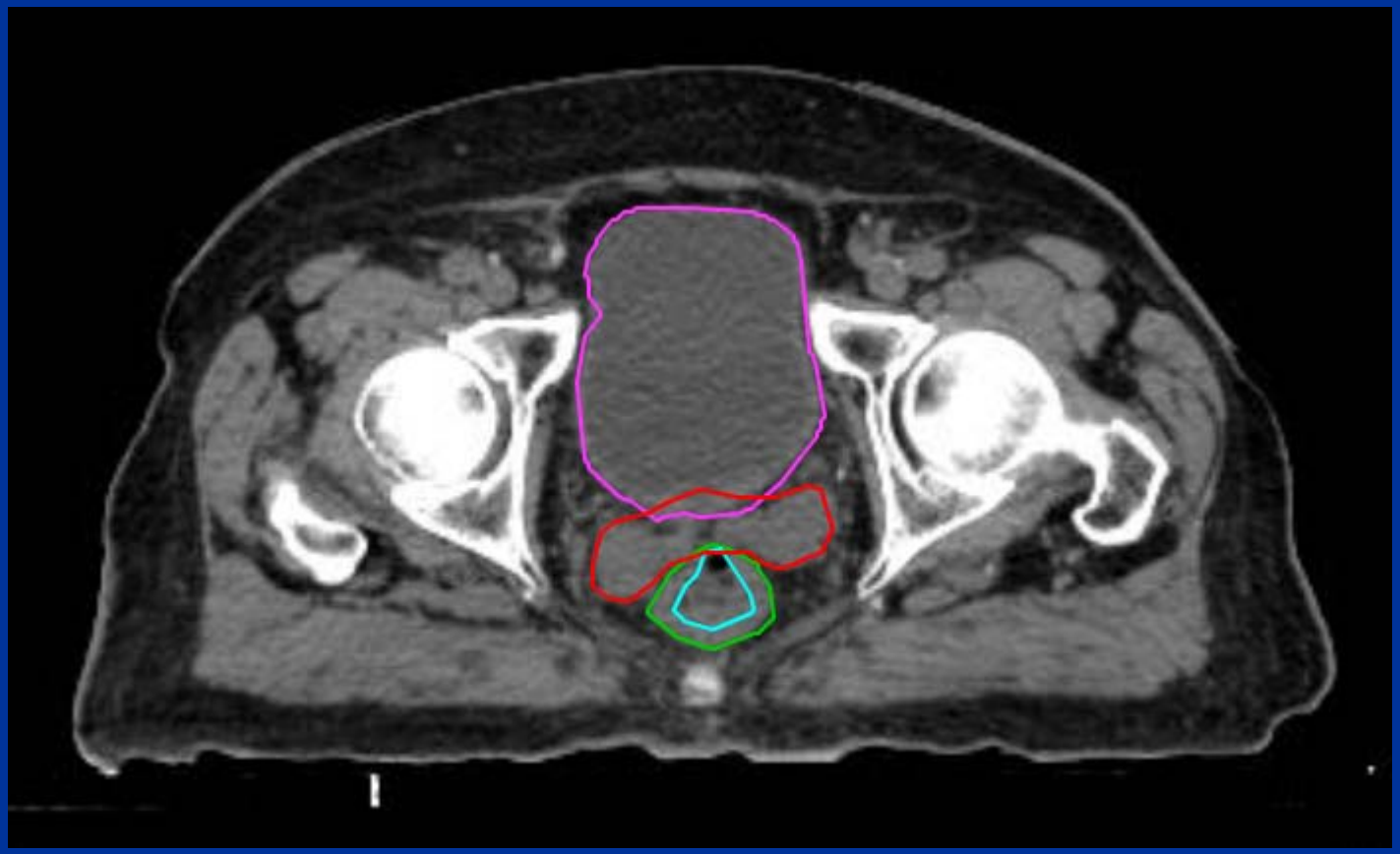

At the Level of SV-with PTV

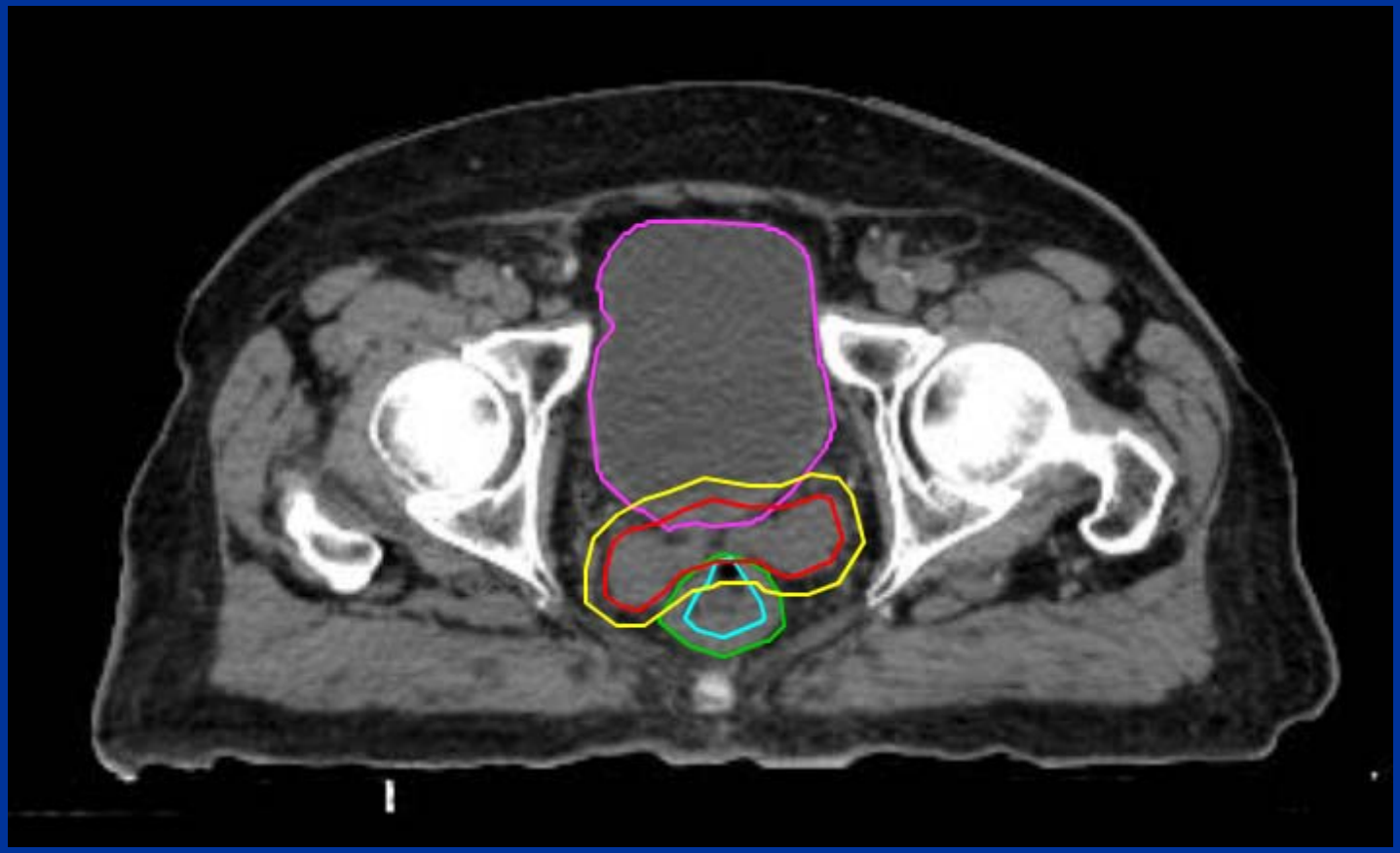

Challenging Areas to Contour

- **Apex**

- **Base**

Errors in Measurement

- Cephalocaudad dimension
  - Identification of the first slice that the base appears
  - Identification of the last section that the apex appears
- Lateral and anteroposterior margins also source of error

Case #5-Apex

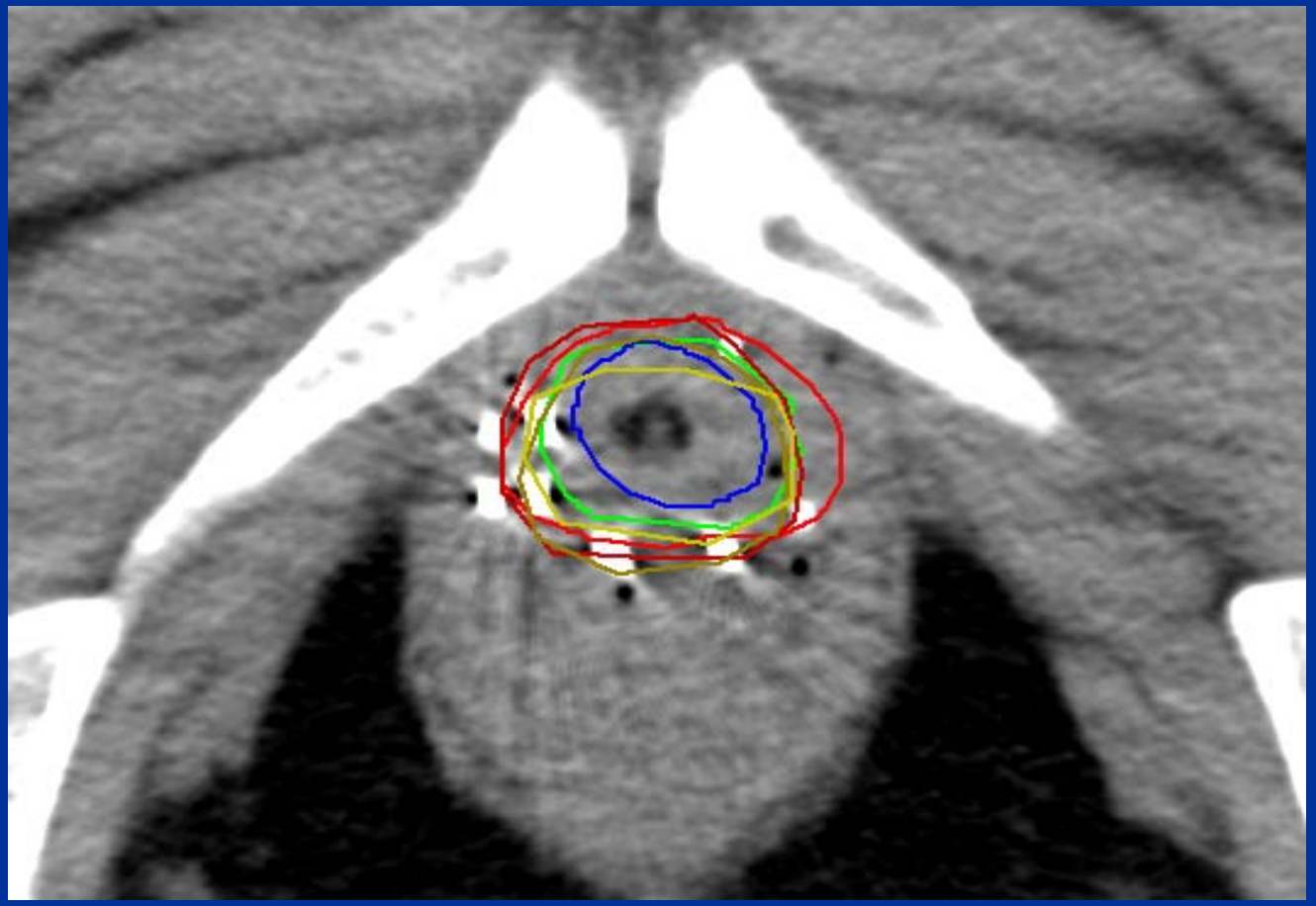

Common Errors in Prostate Contouring

- Overestimating the extent of the apex
- Underestimating the extent of the base
- Widening contours to include levator muscles or peri-prostatic tissues and ligaments

Identification of the Prostatic Apex Looking for the Penile Bulb

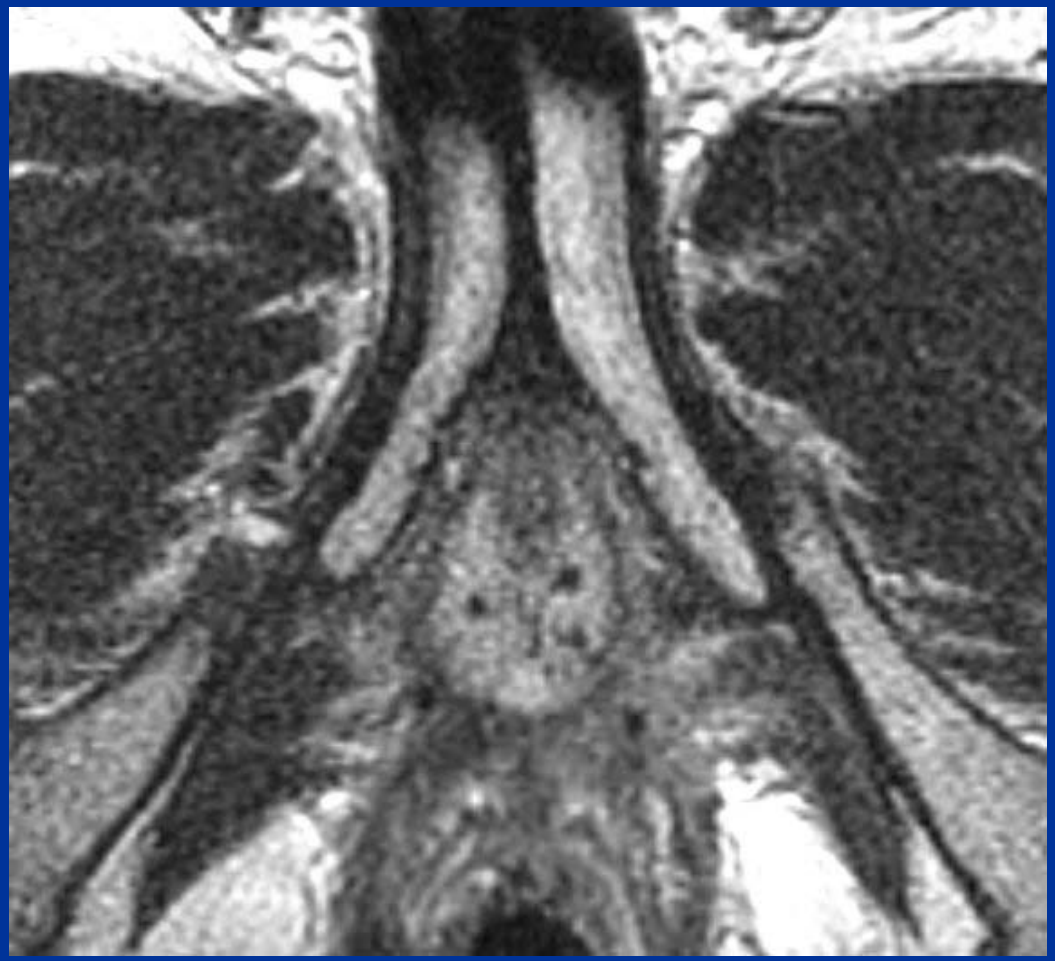

Apical Region

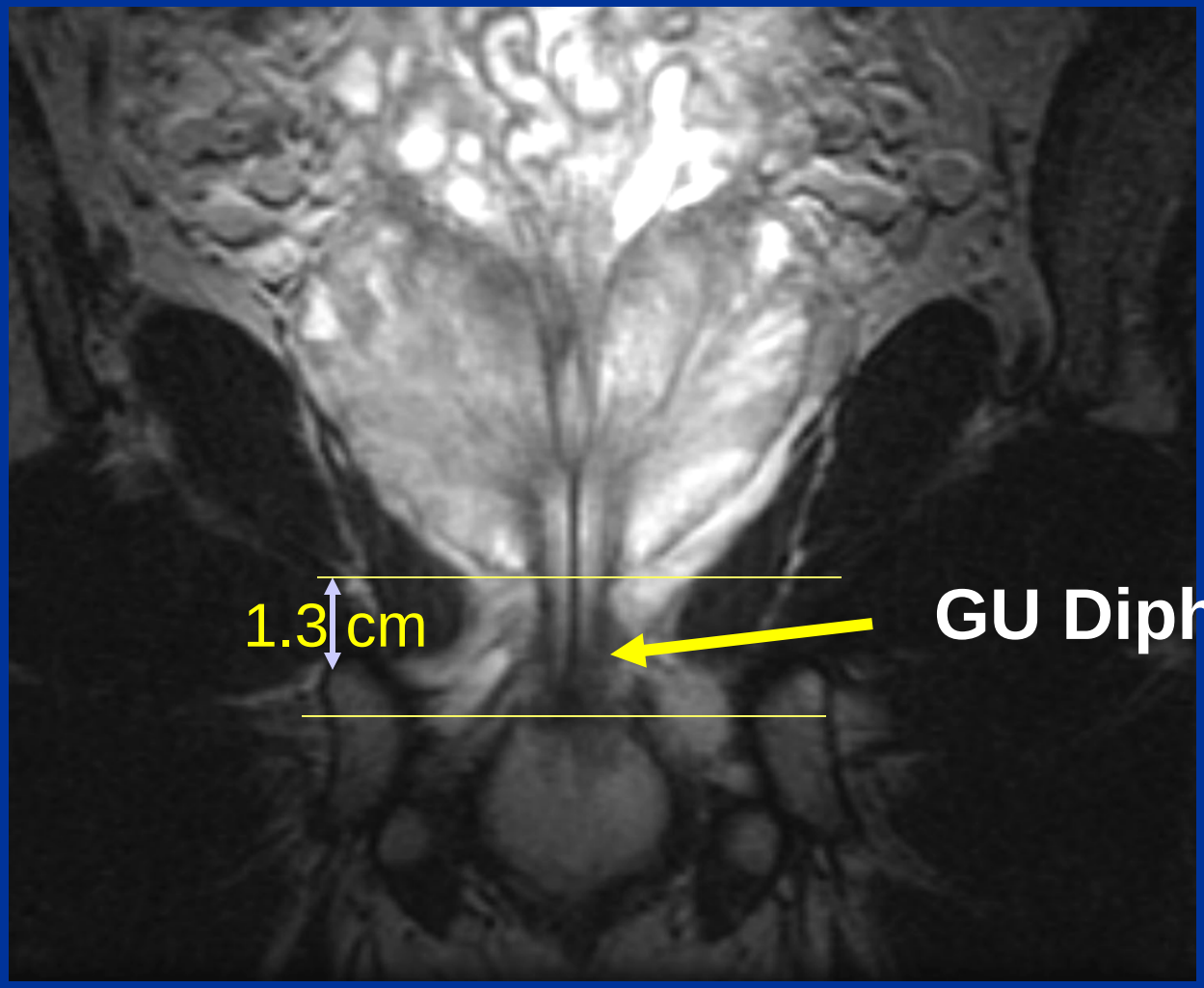


Image #: 17
Position: -151.35 cm
Prostate
Area: 10.88 cm²
Volume: 40.79 cm³
Image #: 18
Position: -151.65 cm
Prostate
Area: 9.86 cm²
Volume: 40.79 cm³
Image #: 19
Position: -151.95 cm
Prostate
Area: 7.51 cm²
Volume: 40.79 cm³
Image #: 20
Position: -152.26 cm
Prostate
Area: 6.48 cm²
Volume: 40.79 cm³
Image #: 21
Position: -152.56 cm
Prostate
Area: 4.99 cm²
Volume: 40.79 cm³
Image #: 22
Position: -152.86 cm
Prostate
Area: 3.34 cm²
Volume: 40.79 cm³
Image #: 23
Position: -153.16 cm
Prostate
Area: 0.00 cm²
Volume: 40.79 cm³
Image #: 24
Position: -153.46 cm
Prostate
Area: 0.00 cm²
Volume: 40.79 cm³
Image #: 25
Position: -153.76 cm
Prostate
Area: 0.00 cm²
Volume: 40.79 cm³
Image #: 26
Position: -154.06 cm
Prostate
Area: 0.00 cm²
Volume: 40.79 cm³
Image #: 27
Position: -154.36 cm
Prostate
Area: 0.00 cm²
Volume: 40.79 cm³
Image #: 28
Position: -154.66 cm
Prostate
Area: 0.00 cm²
Volume: 40.79 cm³

User Interface – “Look ahead – Look back”

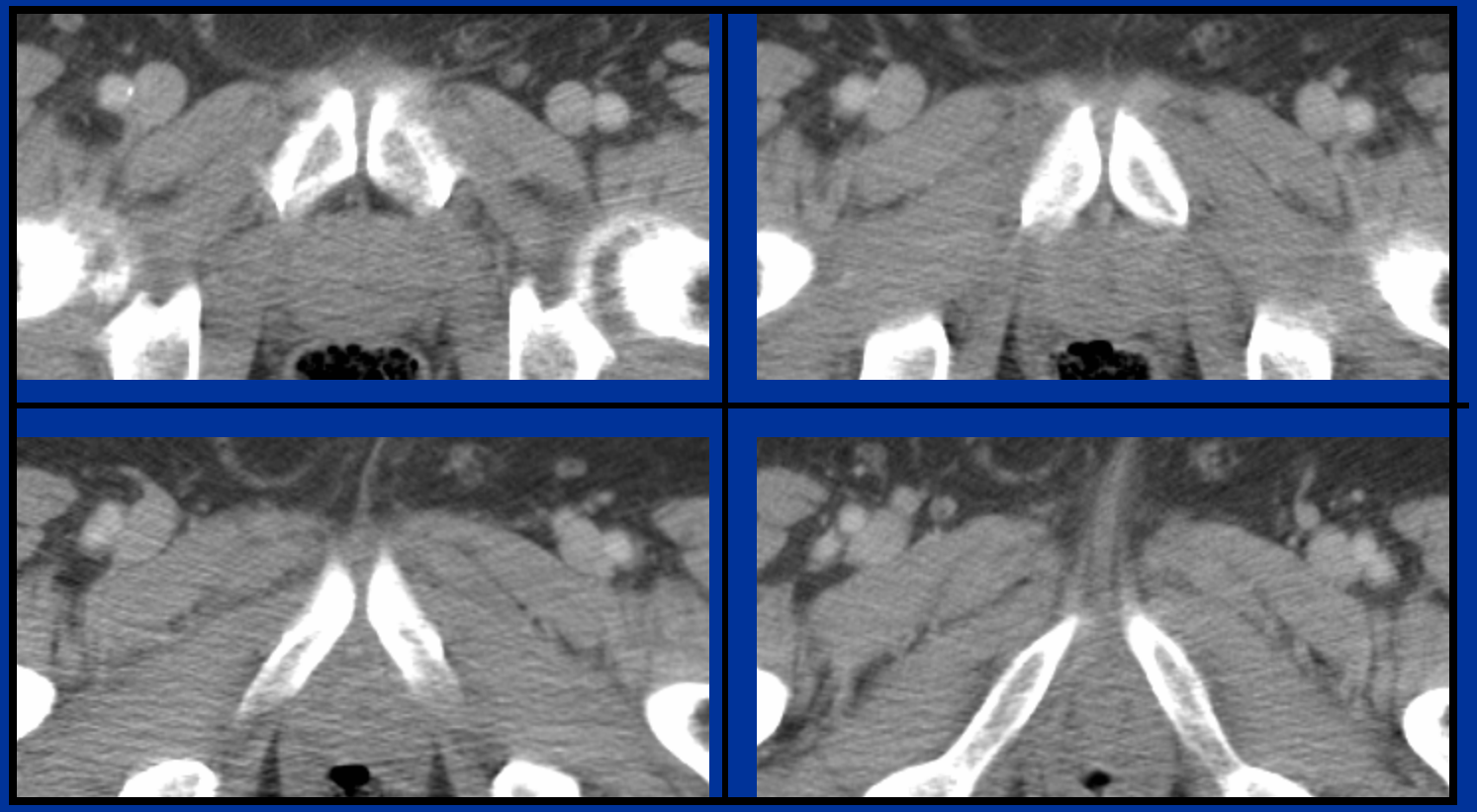

Below Apical Region

Identification of Membranous Urethra

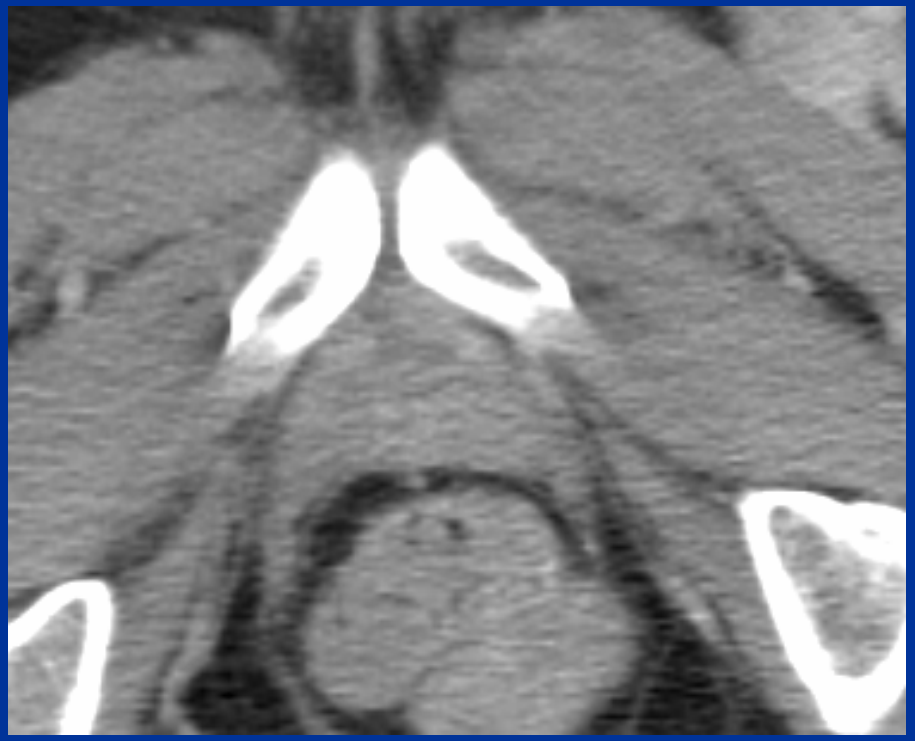

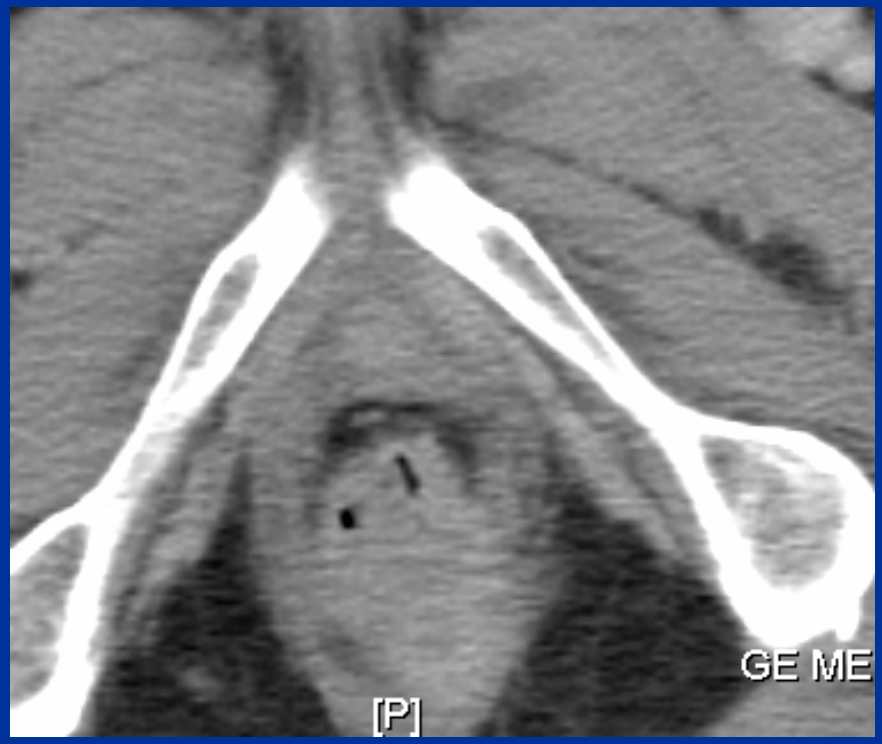

MRI anatomic correlation:
can help improve accuracy of our target delineation for CT-based treatment planning

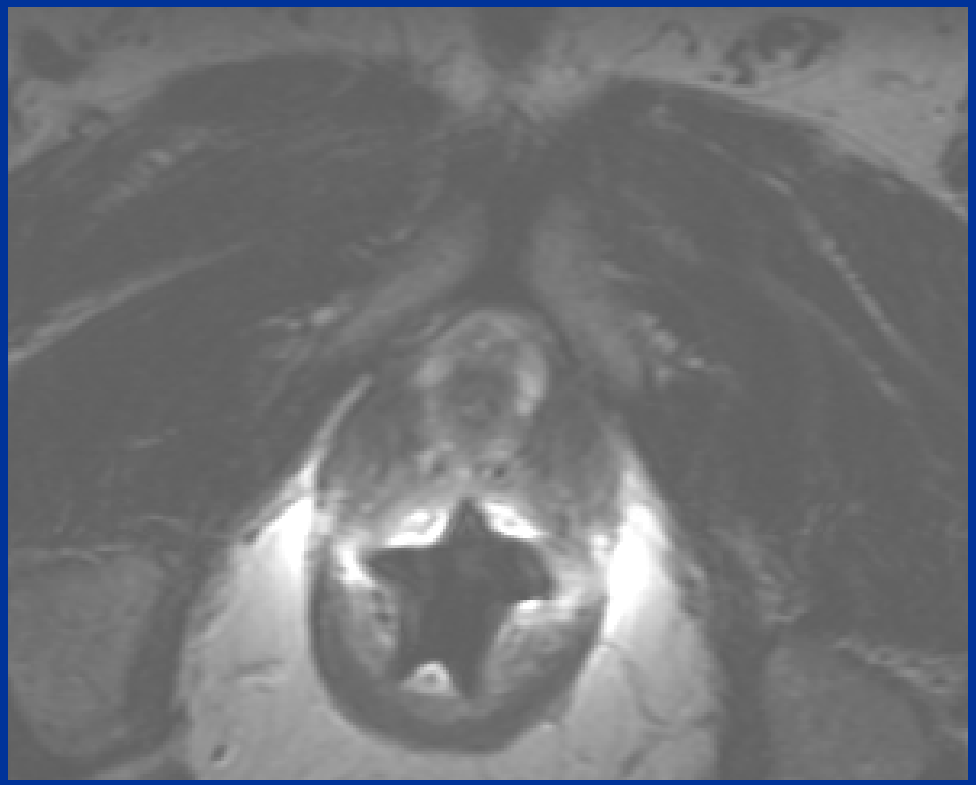


P

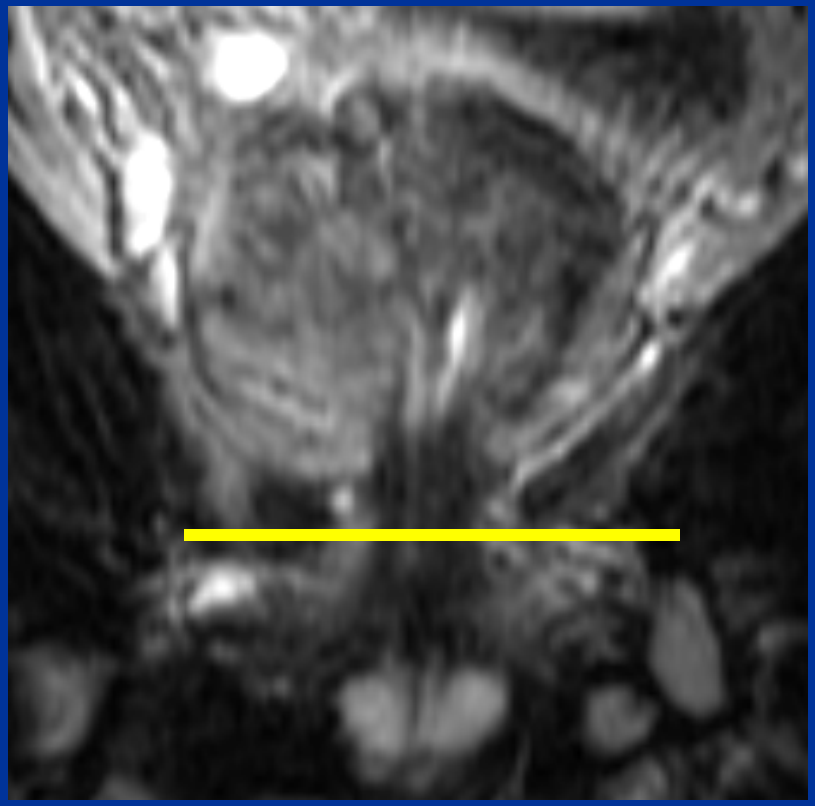

Transition between Apex and GU Diaphragm

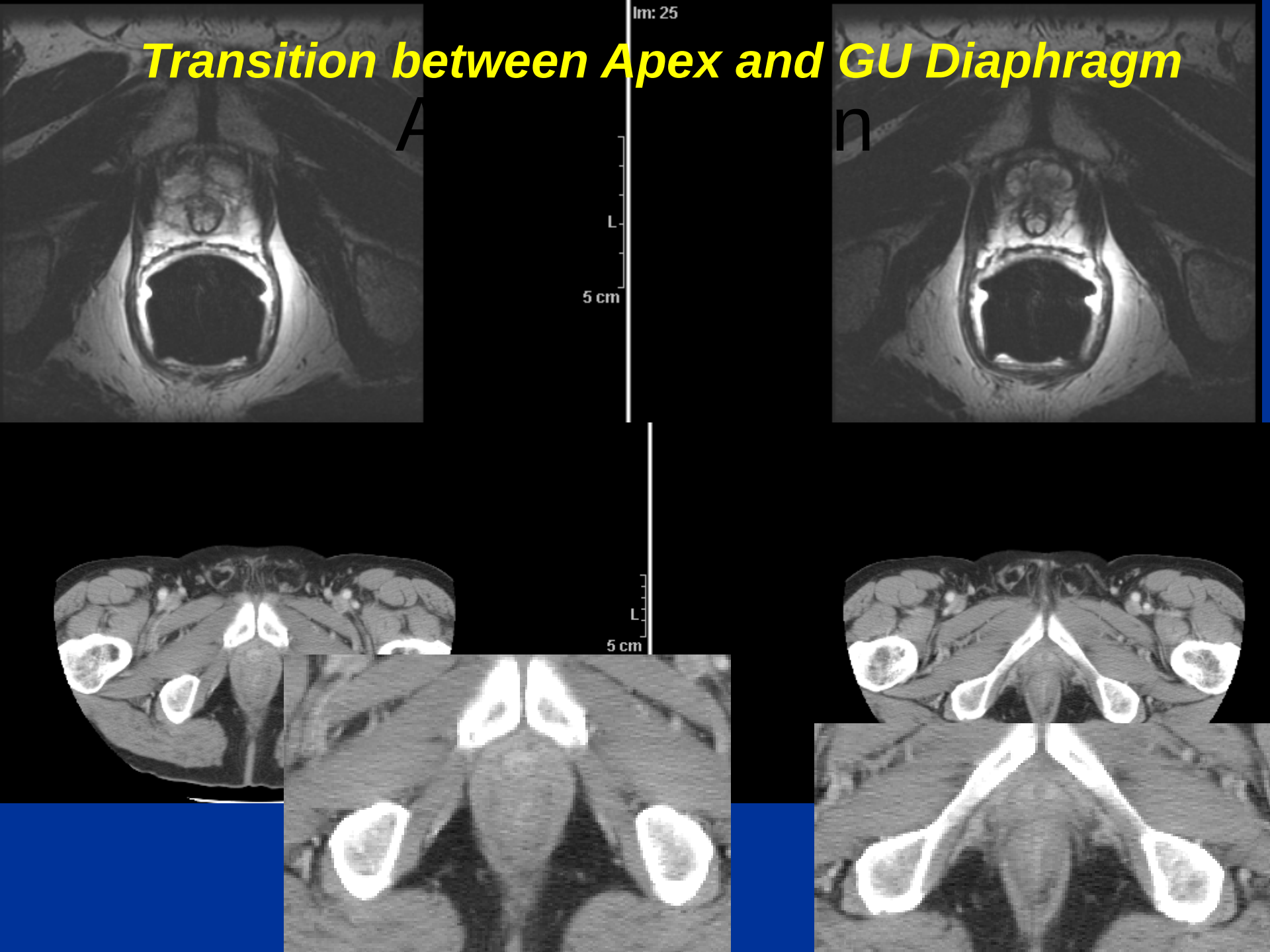

MRI Configuration at the Prostatic Apex
McLaughlin et al IJROBP 2009

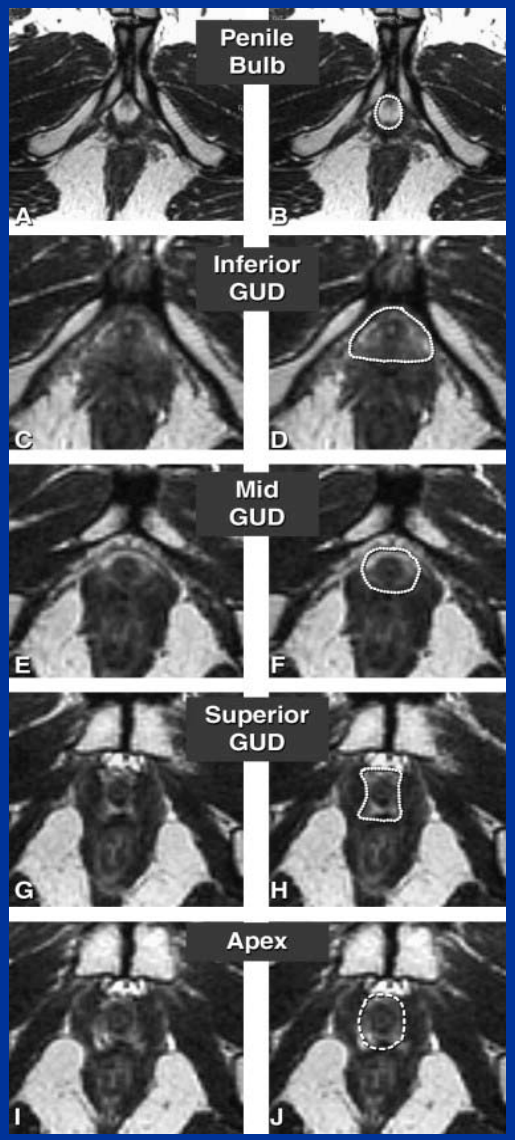

CT Configuration at the Prostatic Apex
McLaughlin et al IJROBP 2009

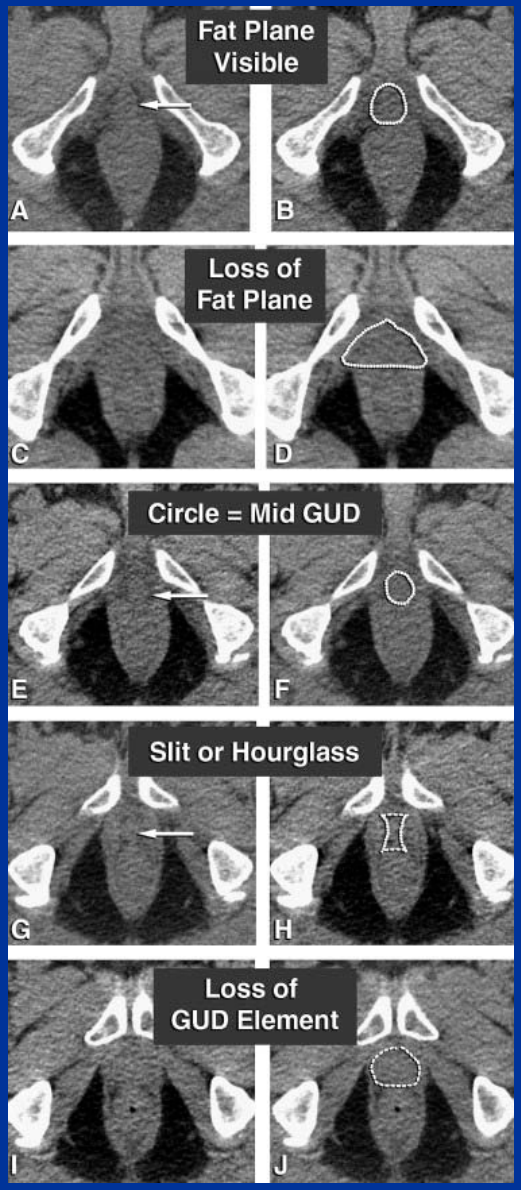

Enhancing Visualization with CT

- Use of IV contrast to delineate apex and base
- Utilization of other imaging modalities
  - Image Fusion with registration
- User Interface – “Look ahead – look back”
  - Real time 3D view / reconstruction
- Comparative with MRI – visual confirmation
  - Most helpful at the base

IV Contrast Enhancement

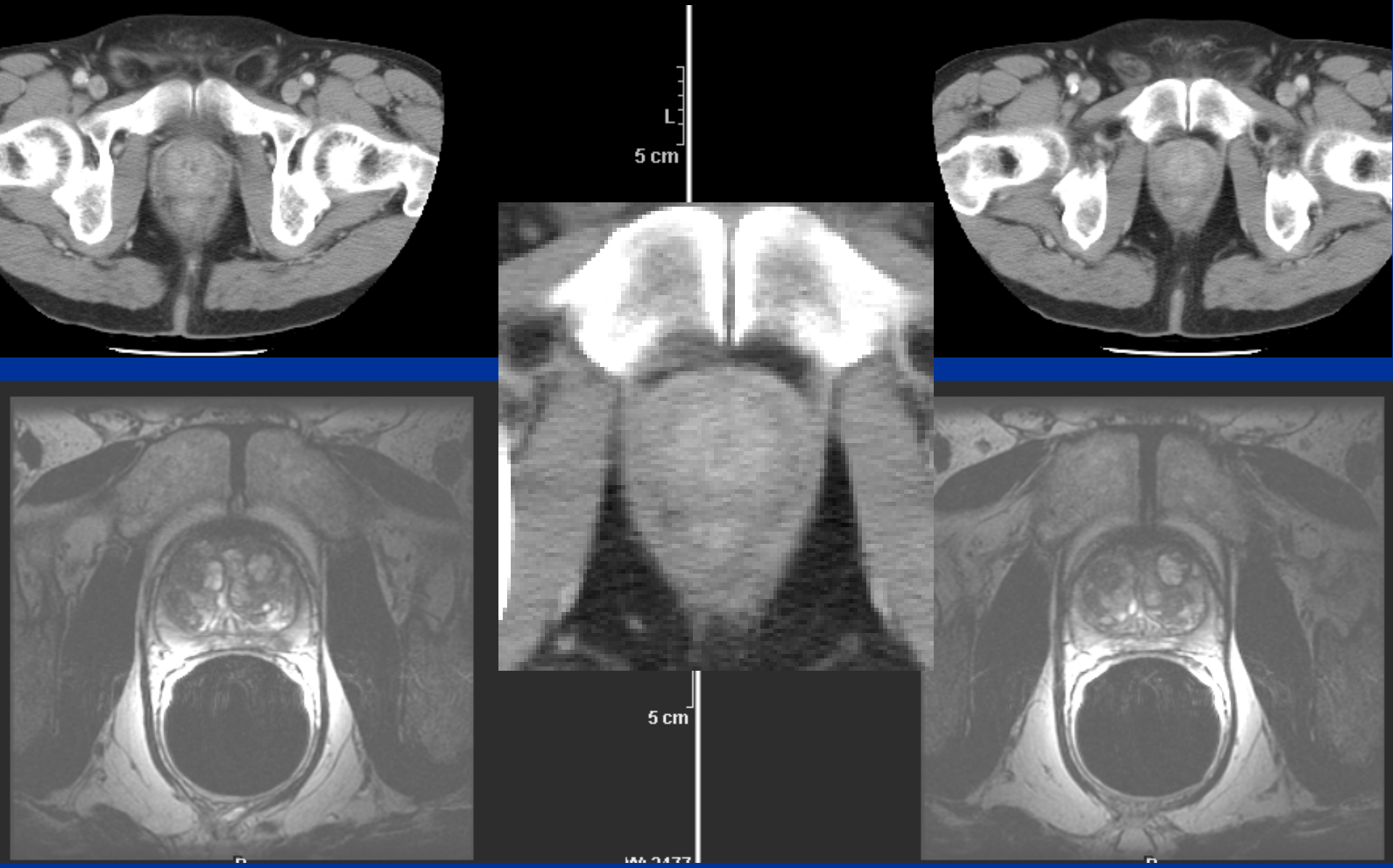

Base of the Gland

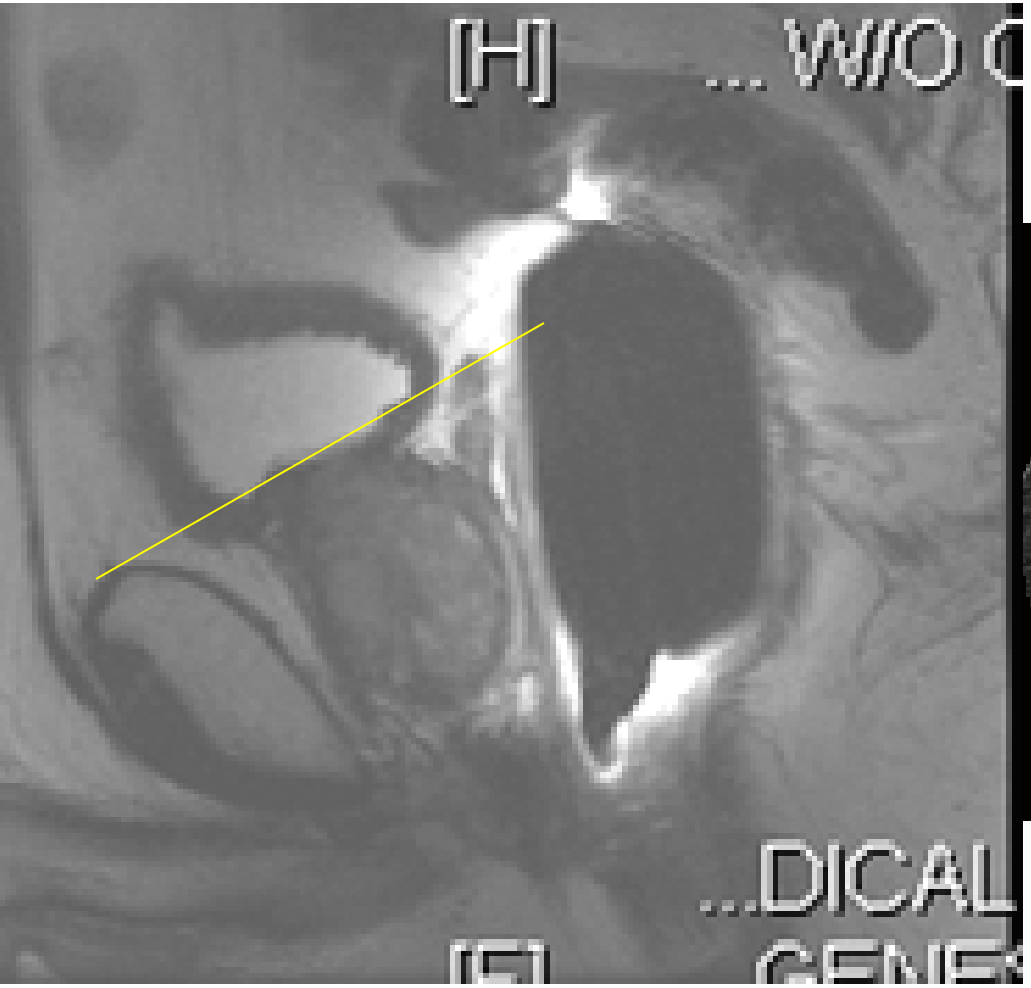

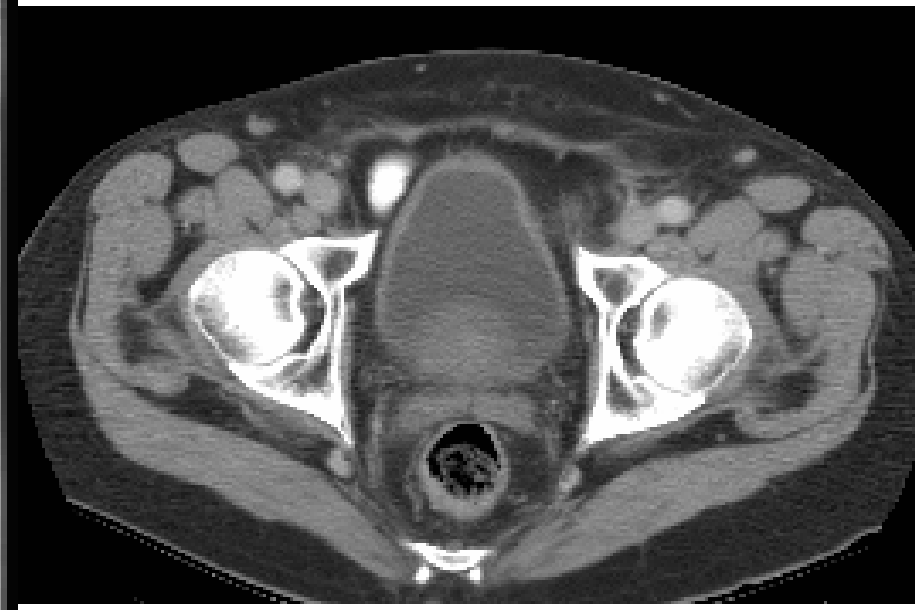

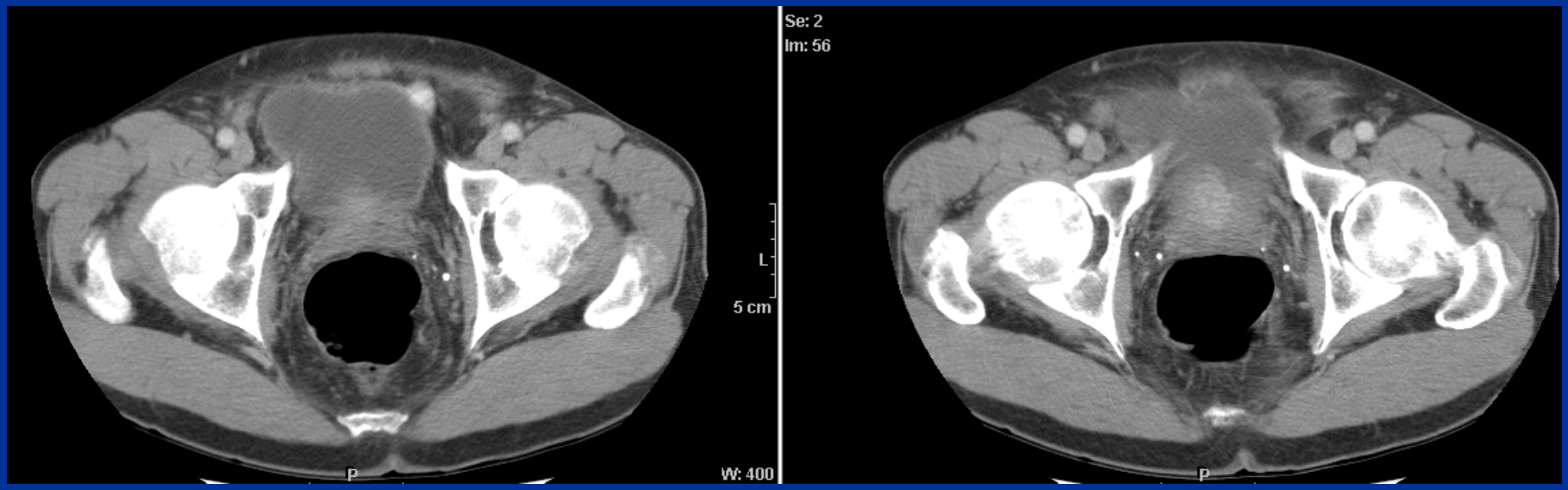
Se: 2
Im: 56
L
5 cm
P
W: 400
P


Im: 15
L
5 cm

Issues at the Prostate Base

McLaughlin et al IJROBP 2009 (in press)

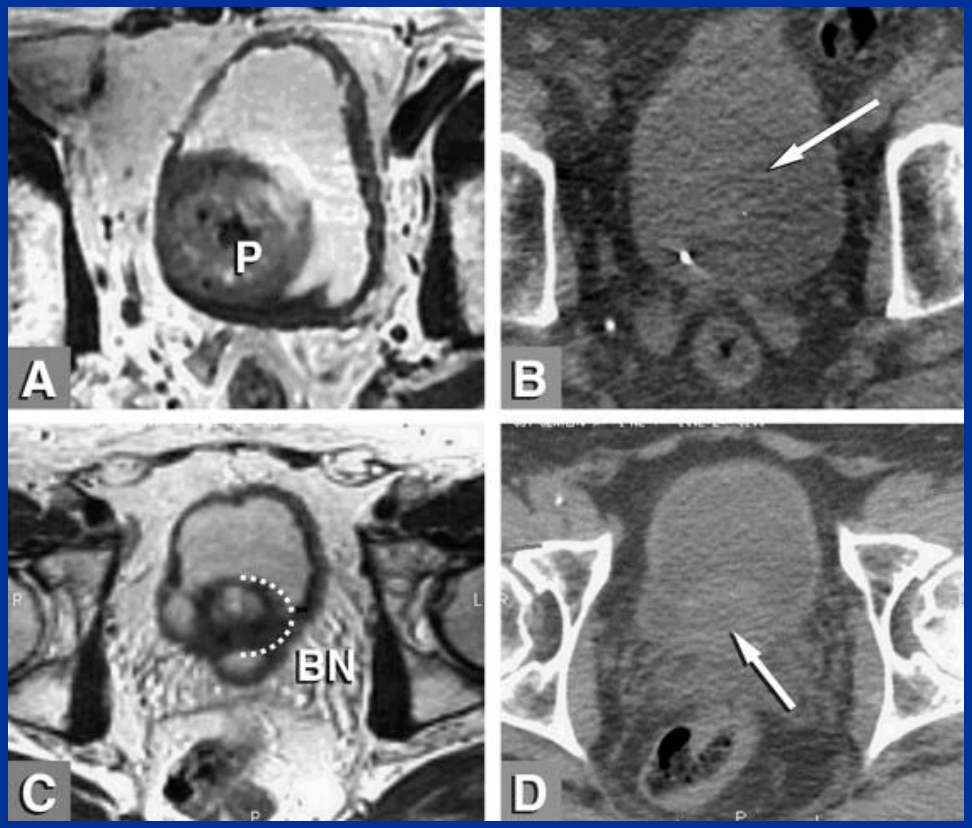

Relationship of the NVB

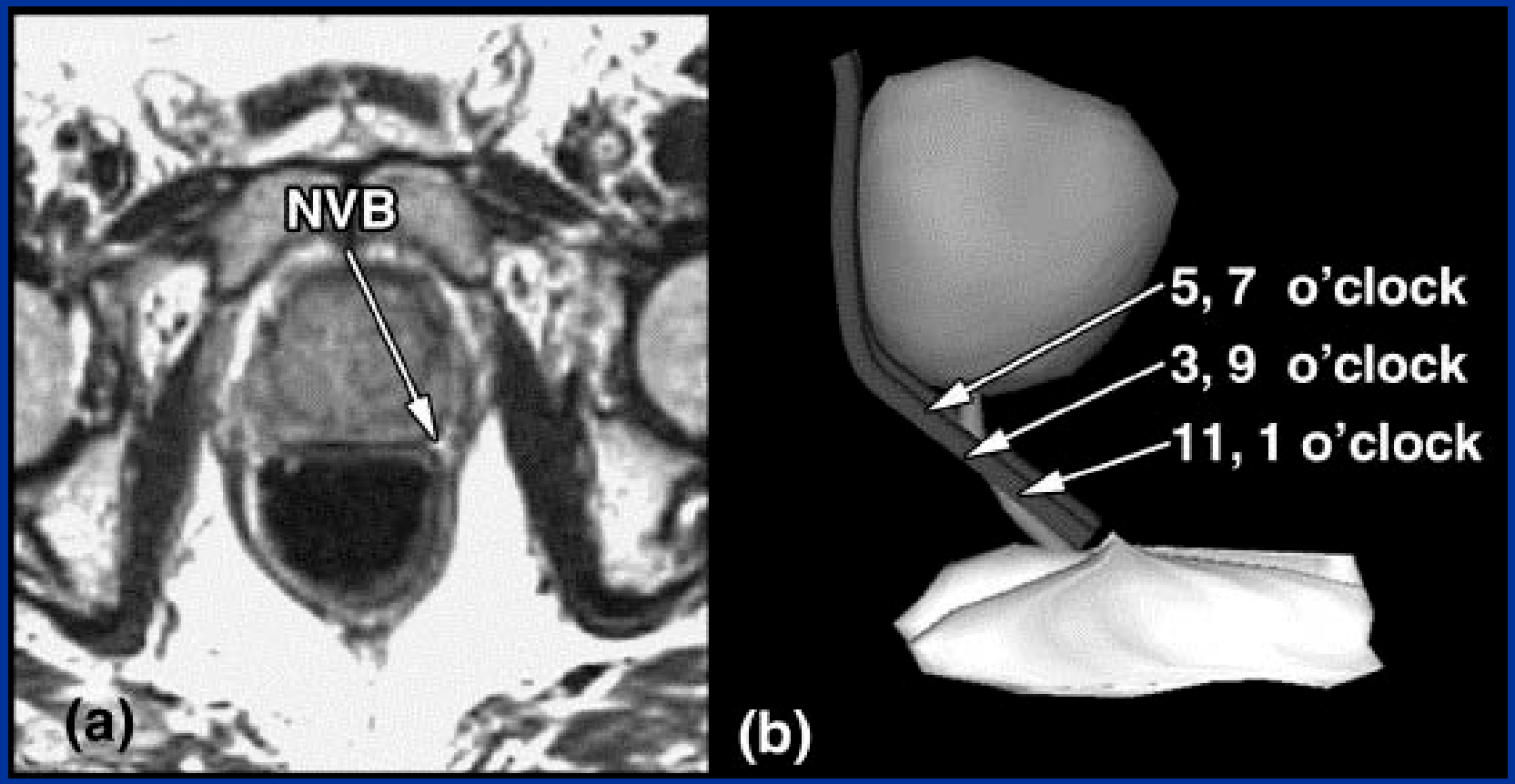

Defining the Prostate Target: Contouring Tips

- Start contouring prostate at mid-gland
- Avoid contouring levator muscles or obturator internis or venous plexi
- As you approach apex apply a “look forward and back approach”
- Identify penile bulb and in general the apex should be located 1-1.5 cm above this landmark

Defining the Prostate Target: Contouring Tips

- For identification of apex and base CT contrast may be helpful
- If intravesical component is present, IV contrast cancan be particularly helpful
- Using beams eye views as you contour will eliminate contours that “jut out or in” too much which probably erroneous

Contouring Post-Op Case General Comments

- Clips help define superior border.
- Volumes generally larger than typical definitive prostate.
- Urine or contrast can define the UV anastomosis which helps define the apex for CTV

Towards the Anastomosis-Apex

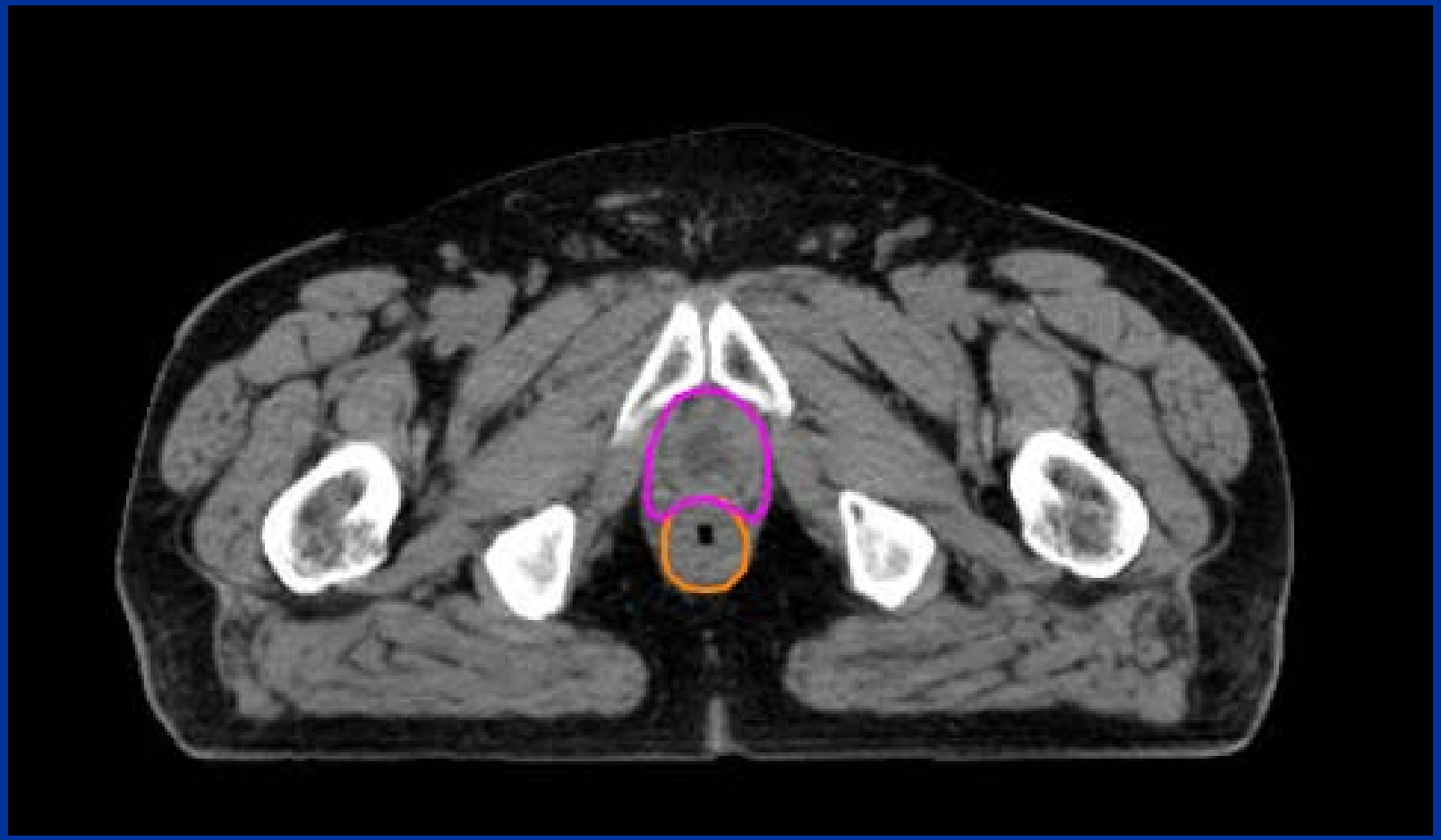

Towards the Anastomosis-Apex

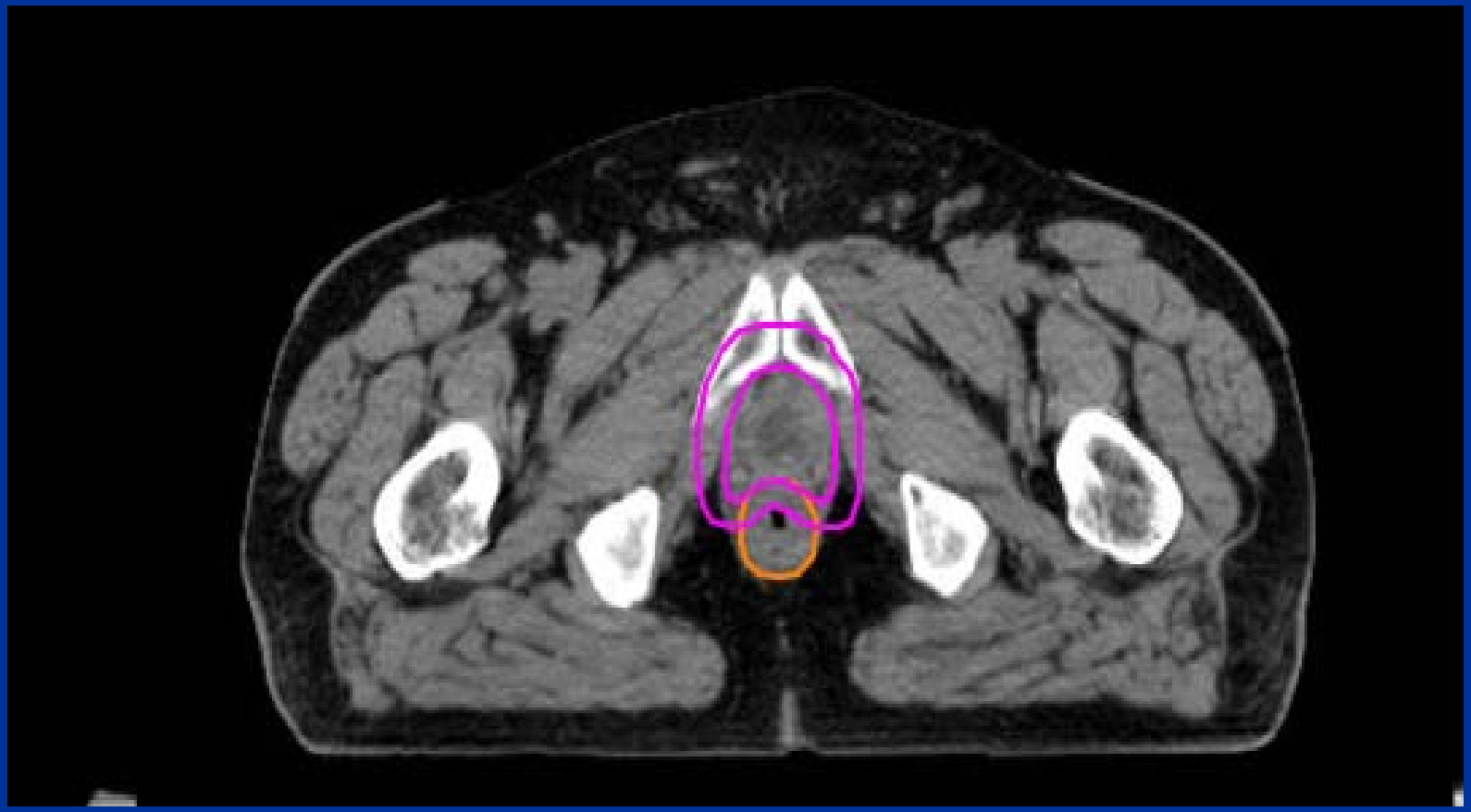

At the Symphysis, begin to Taper CTV

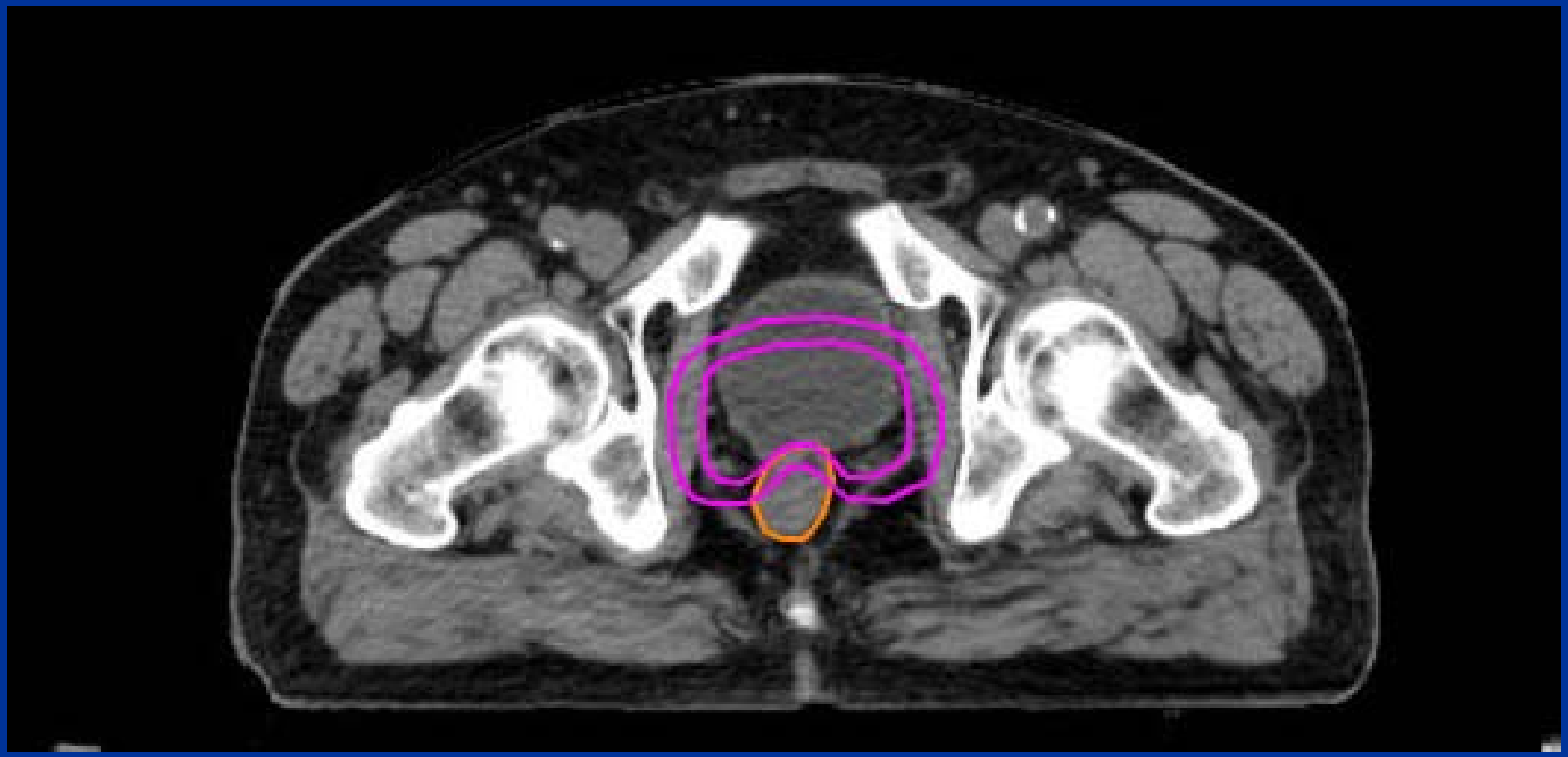

Status Post Robotic RP At the Base- Covering SV Remnants- No Clips Placed

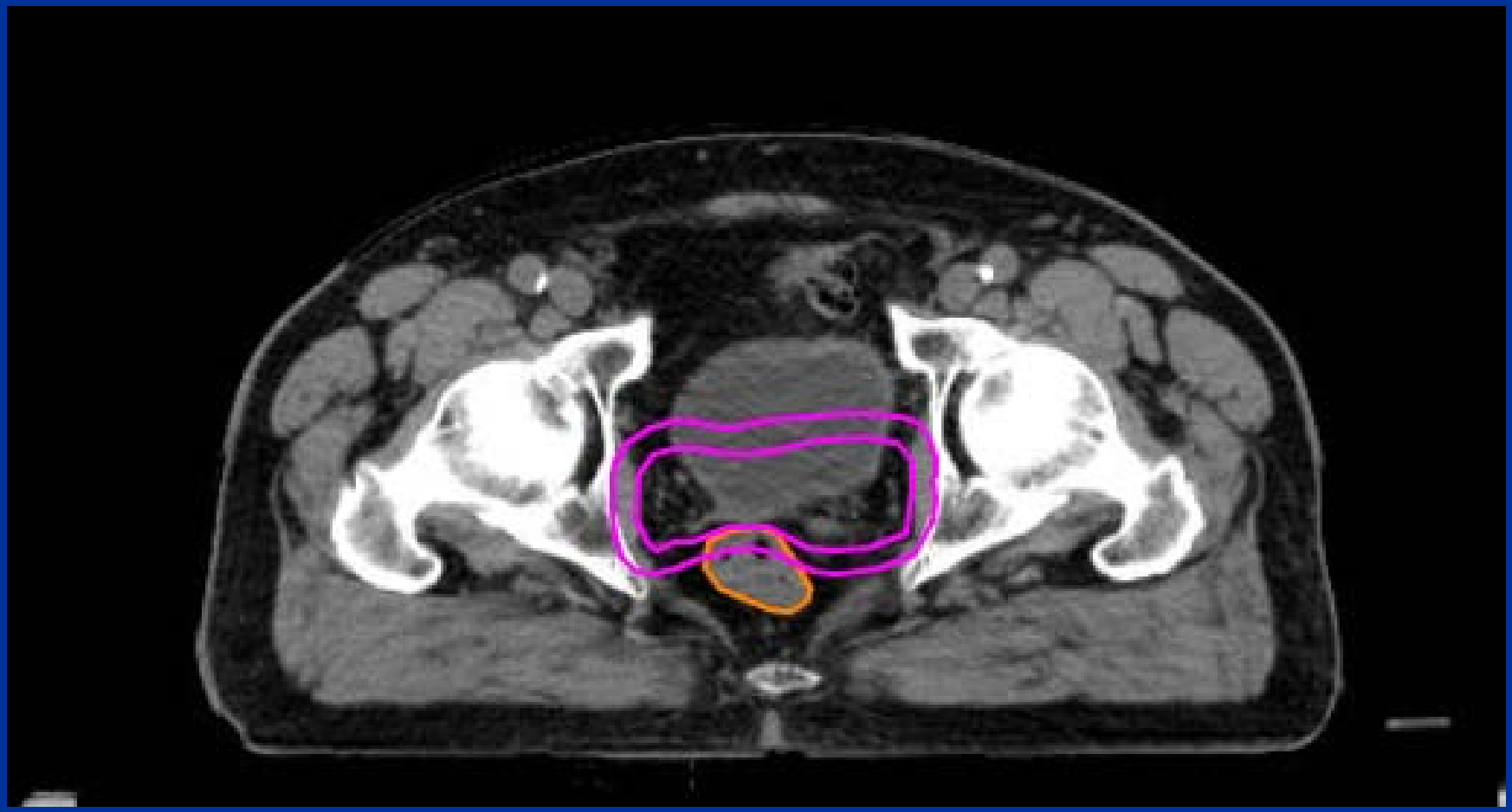

Contouring Post-Op Cases

- Superior Aspect: Include the clips and any residual seminal vesicle remnants.
- Mid-Gland:
  - Include bladder up with lateral inclusion up to the obturator internis muscles.
  - Start tapering the volume as you approach the supeior aspect of the pubic symphysis
- Apex: 1 cm below the UV anastamosis

What about nodes?

3 options:

1. Nodes+prostate to 45 with 3DCRT, then prost with IMRT
2. Nodes+prostate to 45 with IMRT, then separate IMRT plan for prost
3. Nodes+prostate in single IMRT plan, but nodes at lower daily fraction size

Institution	*Nodes and IMRT?*
UM	Option 1: 3DCRT then IMRT
FCCC	Option 3: Single plan IMRT
Wash U	Option 2: Two IMRT plans
Wisconsin	Option 3
Duke	Option 2
Jefferson	Option 1
ROC	Option 2
MCW	Option 2
Mayo	Option 2
MSKCC	Option 2

Contouring of Pelvic Lymph Nodes

- Give IV contrast for target visualization
- Superior aspect at L5-S1
- At MSKCC 1-1.5 cm margin drawn for PTV around nodal or vascular structures

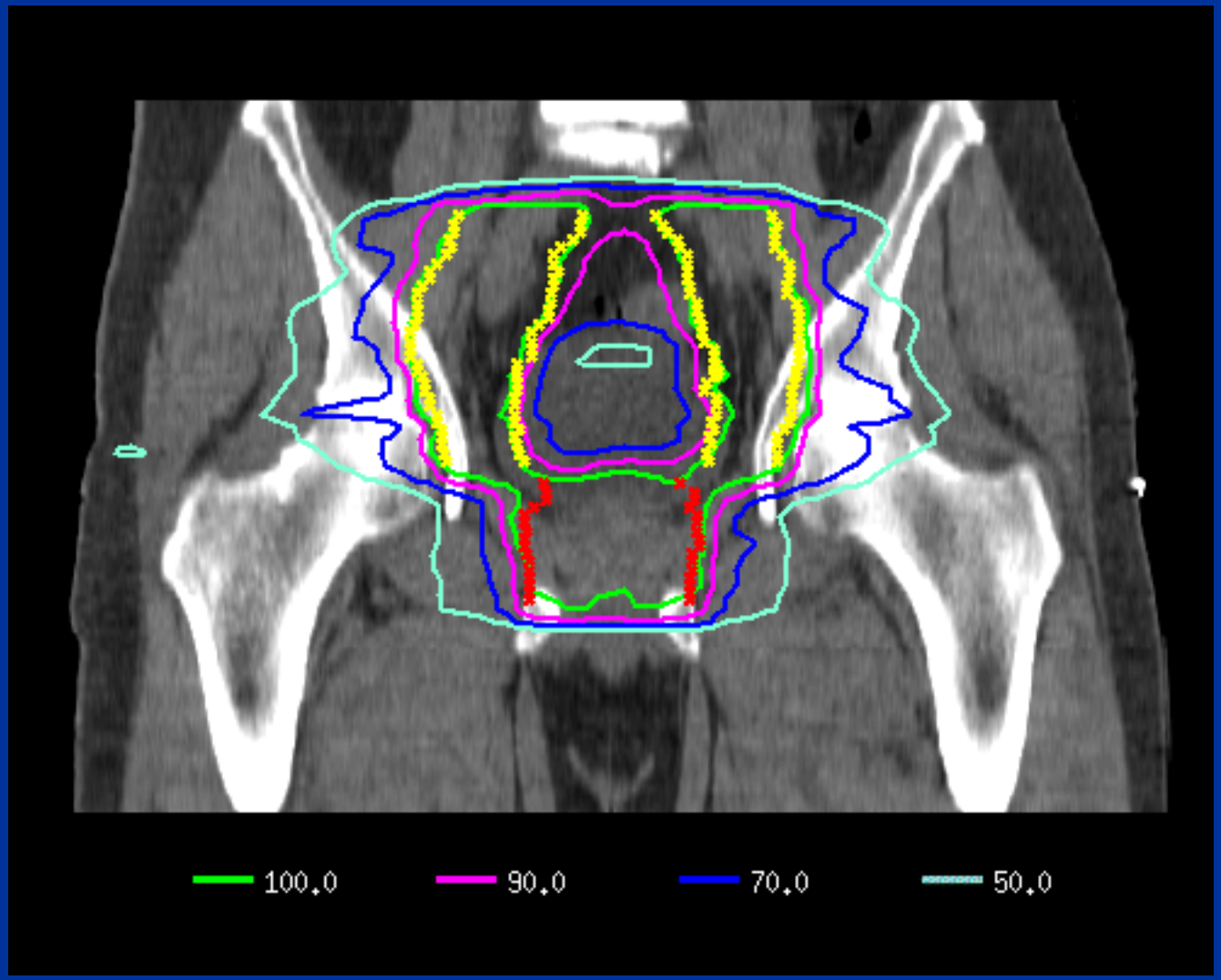
100.0
90.0
70.0
50.0

Conclusions

- Familiarize yourself with the anatomic borders of the prostate
- After contouring mid-gland levels, turn attention to apex and apply look ahead and back approach
- IV contrast especially for large intravesicle component can be helpful
- Knowing extent and location of intra-prostatic disease should fine tune the delineation of your PTV for more generous margin